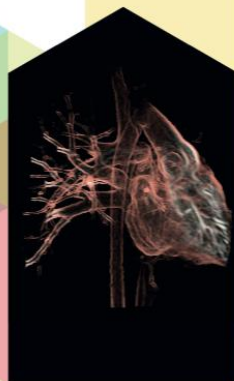


VI CORSO GUCH

Il paziente adulto con cardiopatia congenita

TORINO
03 DICEMBRE 2022
NH TORINO CENTRO



L'imaging: non solo ventricolo destro



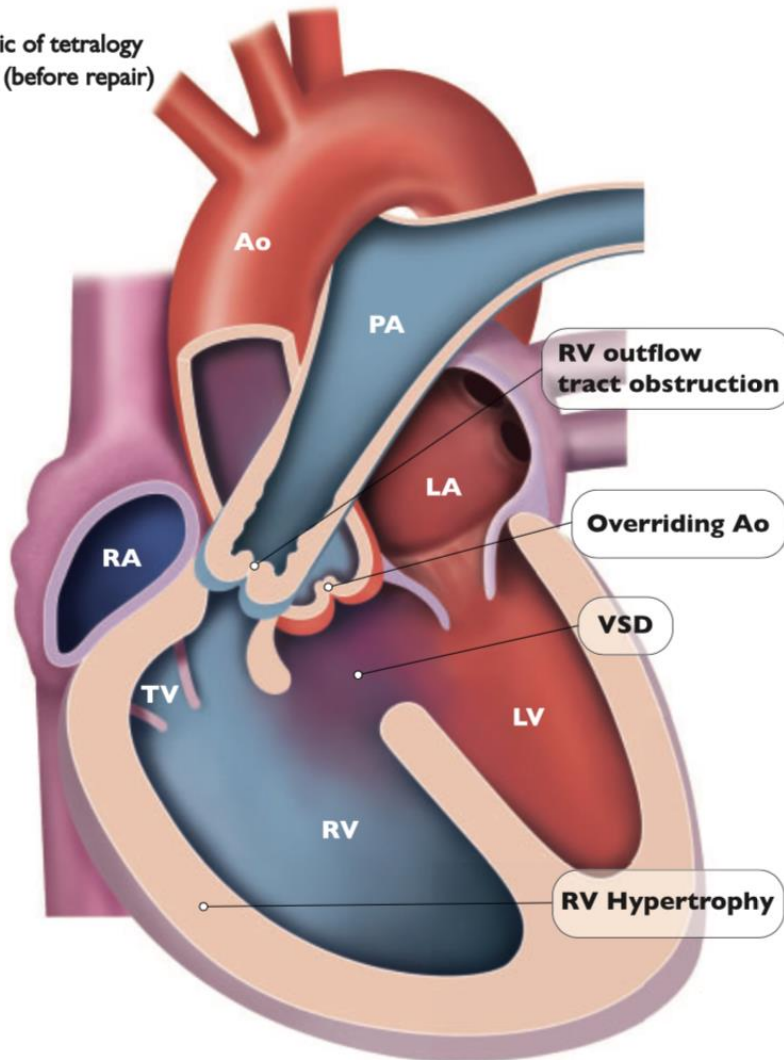
Francesca Ferroni

Cardiologia pediatrica

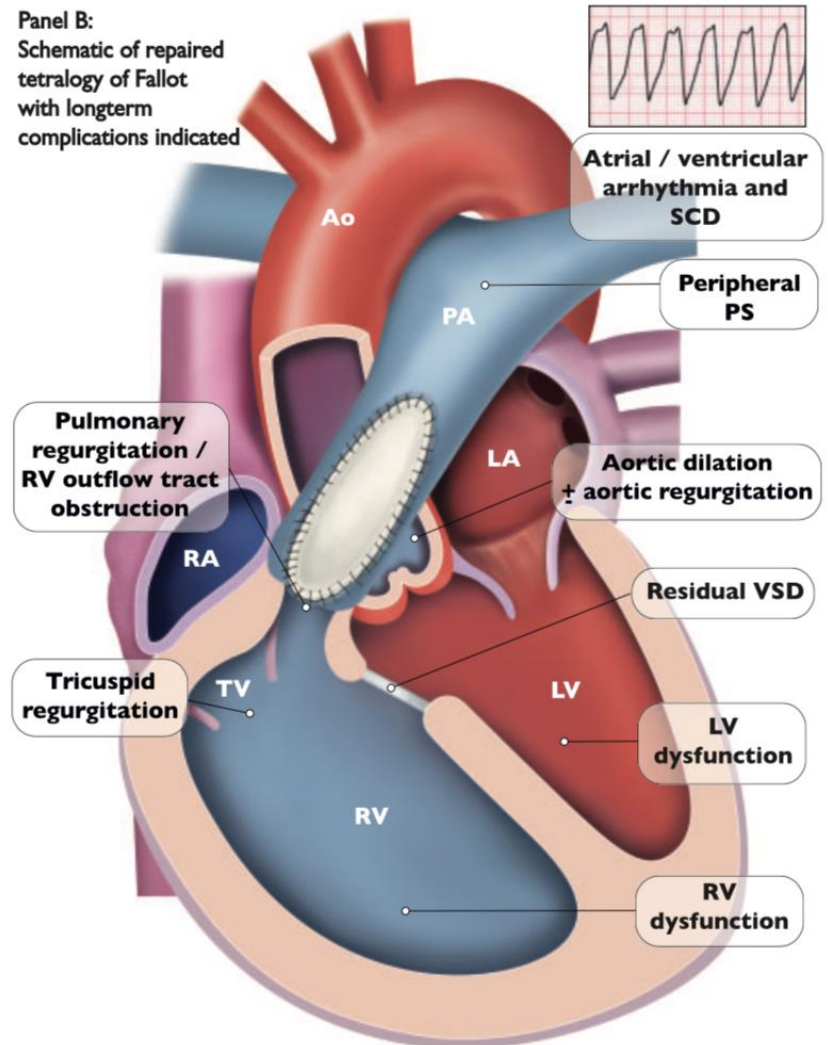
Ospedale Regina Margherita, Torino, Italy

Tutto origina da una deviazione anteriore del setto conale

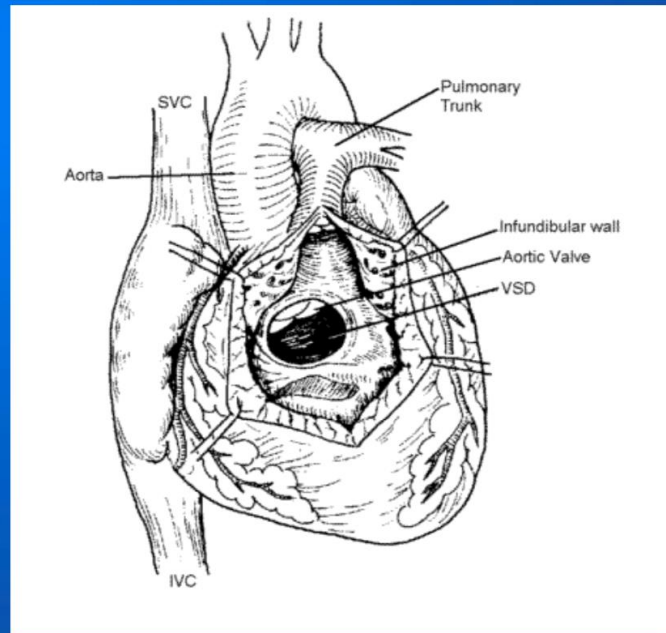
Panel A:
Schematic of tetralogy
of Fallot (before repair)



Panel B:
Schematic of repaired
tetralogy of Fallot
with longterm
complications indicated



La prima cardiopatia congenita complessa ad essere stata chirurgicamente palliata e poi corretta

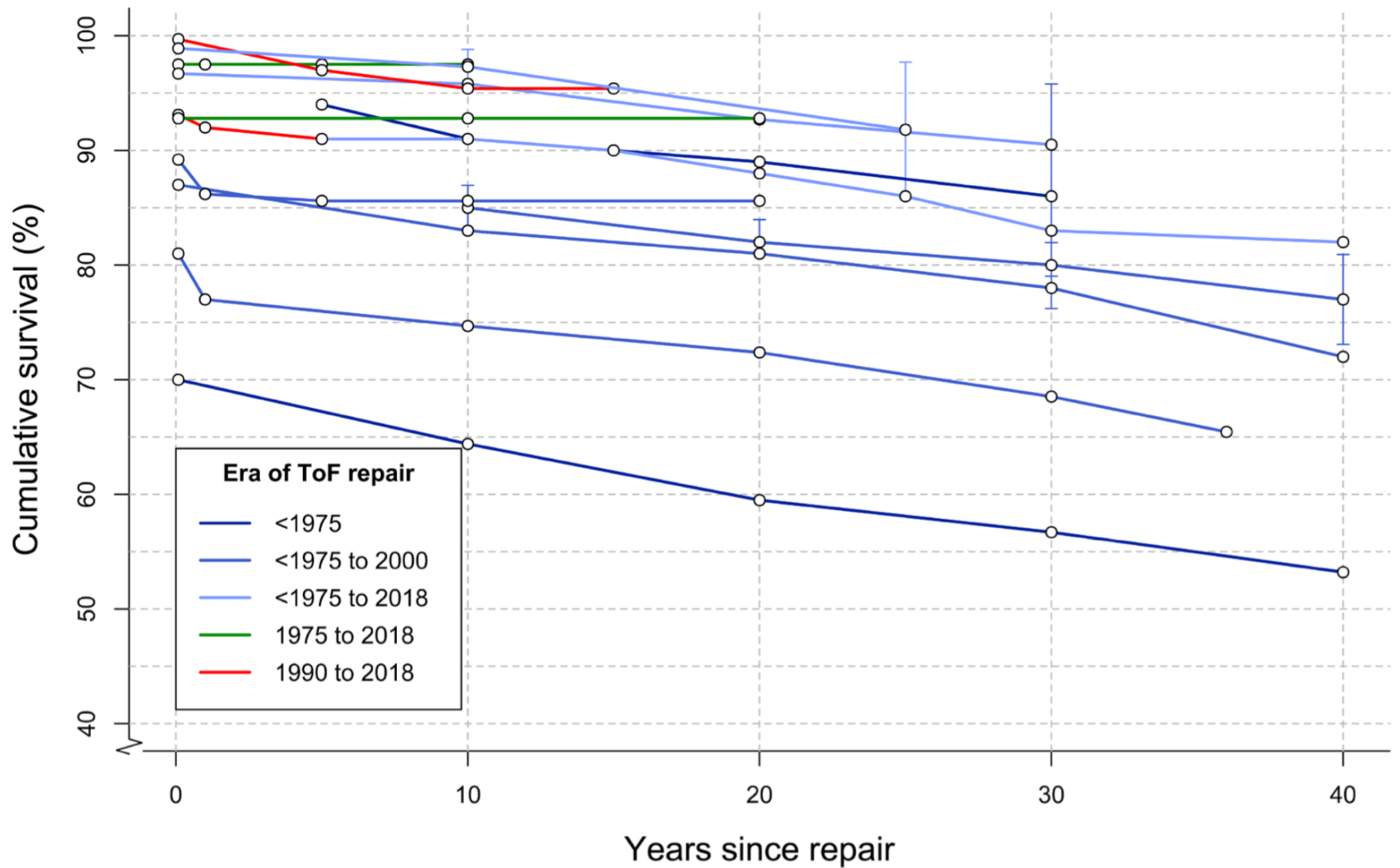


Lillehei: 1954: First total correction

Lillehei CW, Cohen M, Warden HE, et al. Direct vision intracardiac surgical correction of the tetralogy of Fallot, pentalogy of Fallot, and pulmonary atresia defects: report of first ten cases.

Ann Surg. 1955; 142: 418–445.

Come è variata la sopravvivenza negli anni



Adults with Tetralogy of Fallot – - Repaired, Yes; Cured, No

Rosenthal A.: N Engl J Med. 1993 Aug 26;329(9):655-6.

PULMONARY REGURGITATION and RVOT DYSFUNCTION



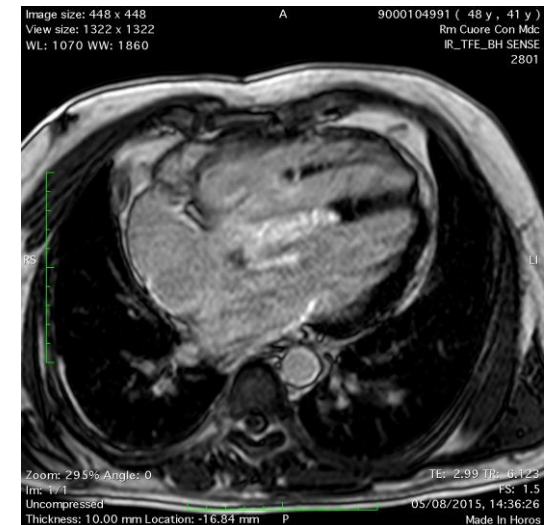
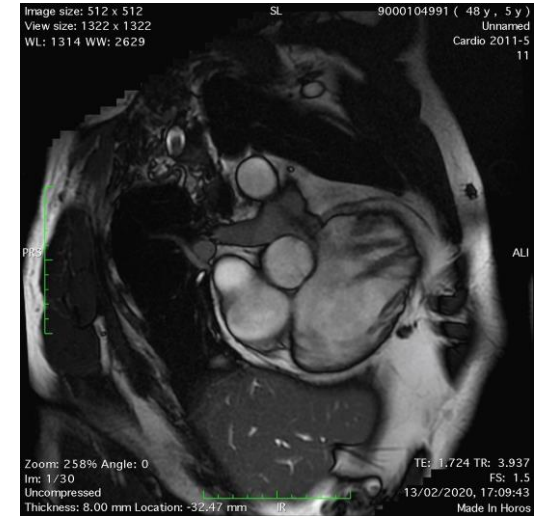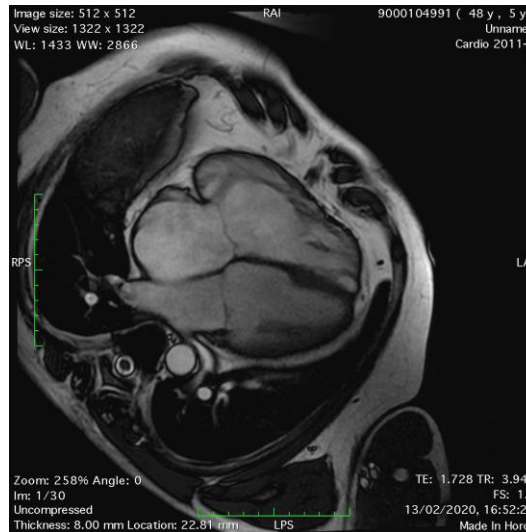
RV DYSFUNCTION and FIBROSIS



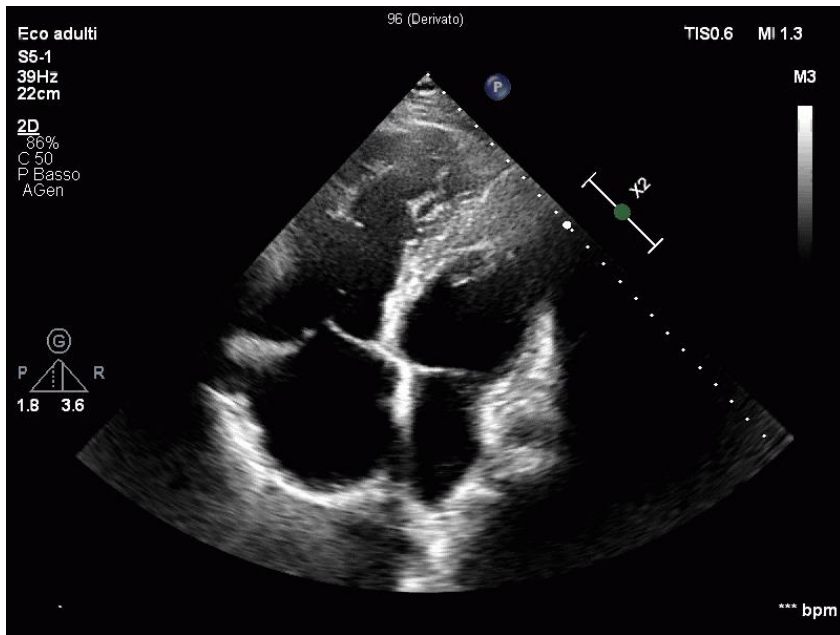
ARRHYTHMIA and LV DYSFUNCTION



SUDDEN DEATH and CHF



Mattia 24 aa



11/3/1999

TOF+MAPCAS s/p a embolizzazione e intervento CCH con monocuspide e chiusura DIV

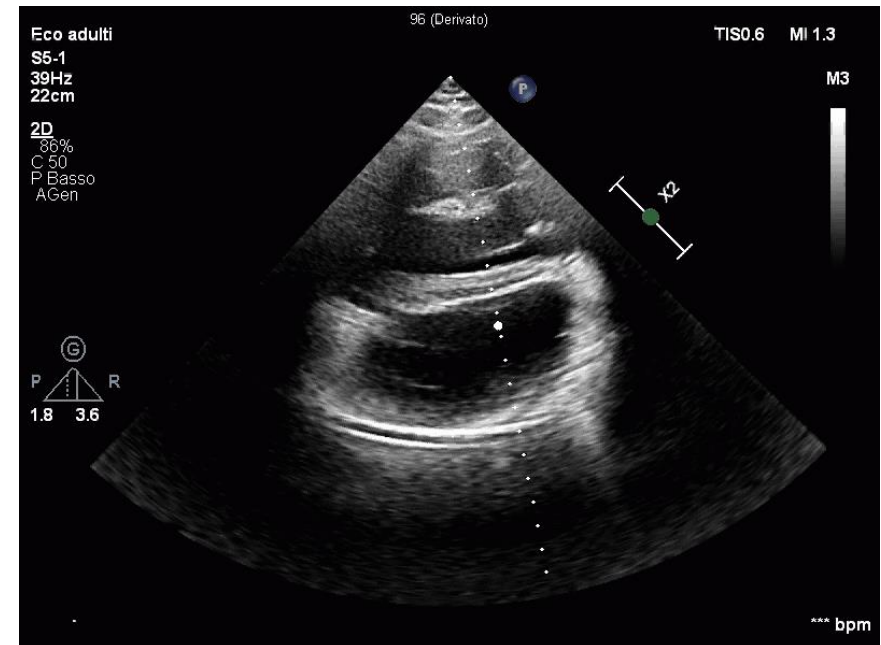
2001

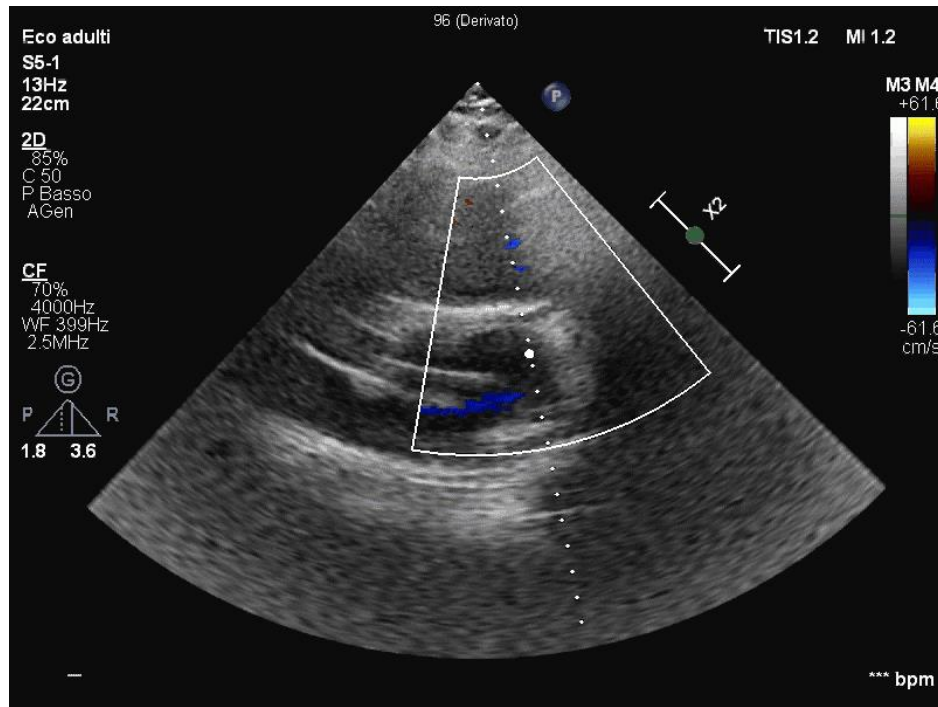
BAV III s/p a impianto di PM poi rimosso per microfrattura

2022

Visita medico sportiva con riscontro di flutter atriale non databile

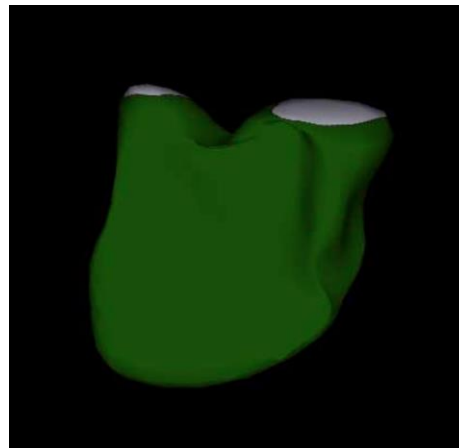

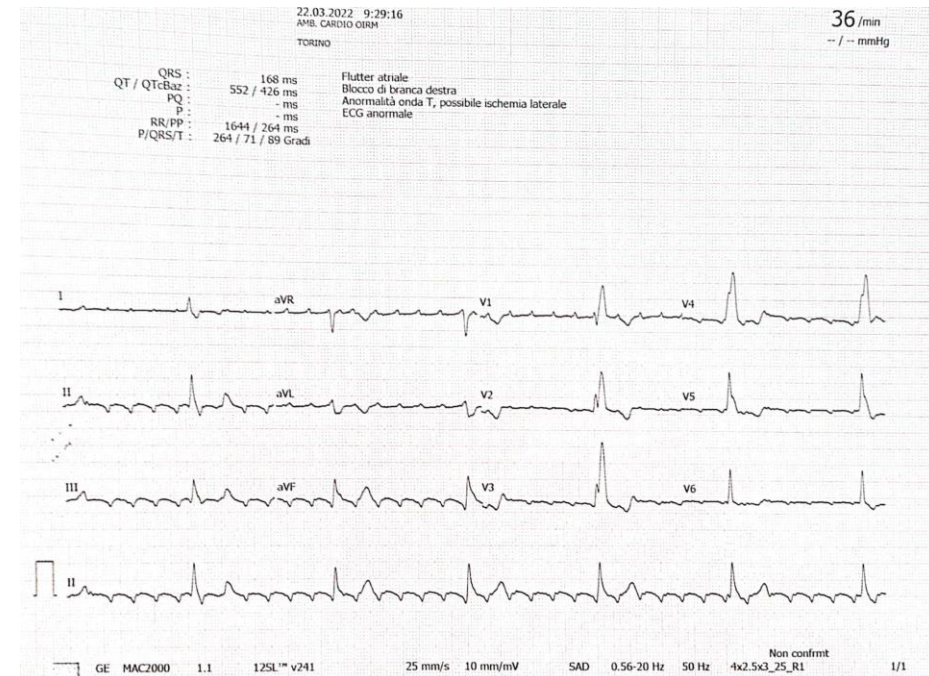
accesso in PS al San Luigi

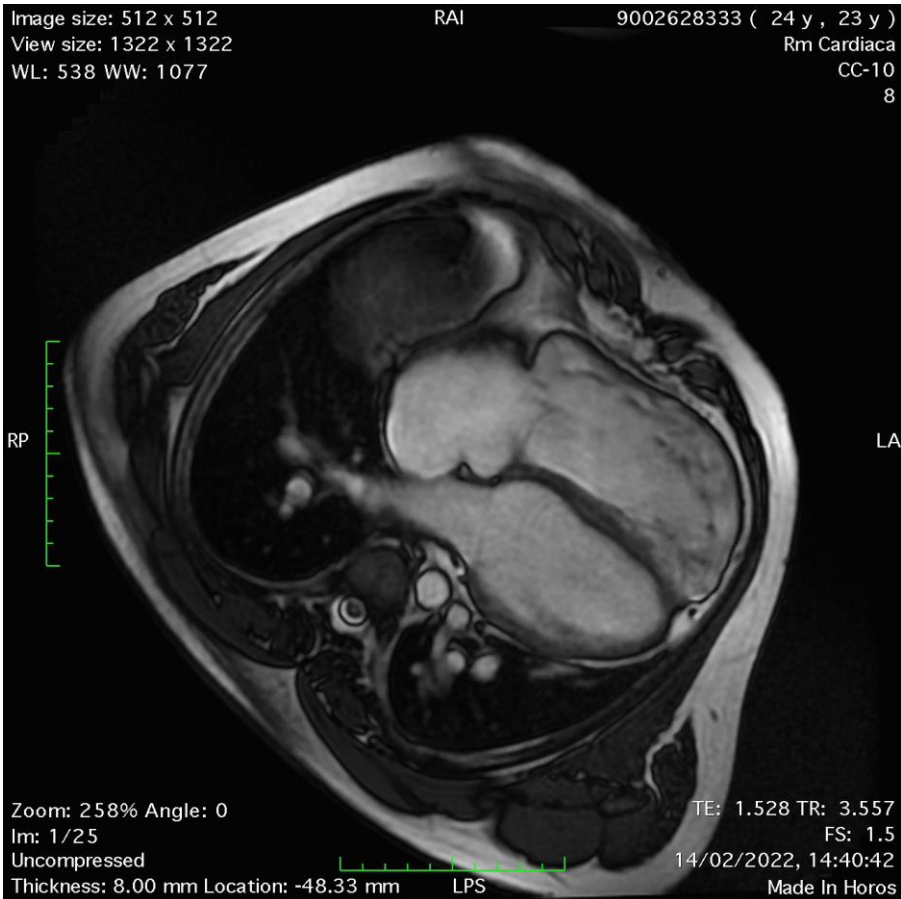




TEST ERGOMETRICO

Flutter atriale 5:1 con FC 44 bpm, graduale incremento fino a 96 bpm, regolare profilo pressorio, discreta tolleranza all'esercizio fisico





VDX

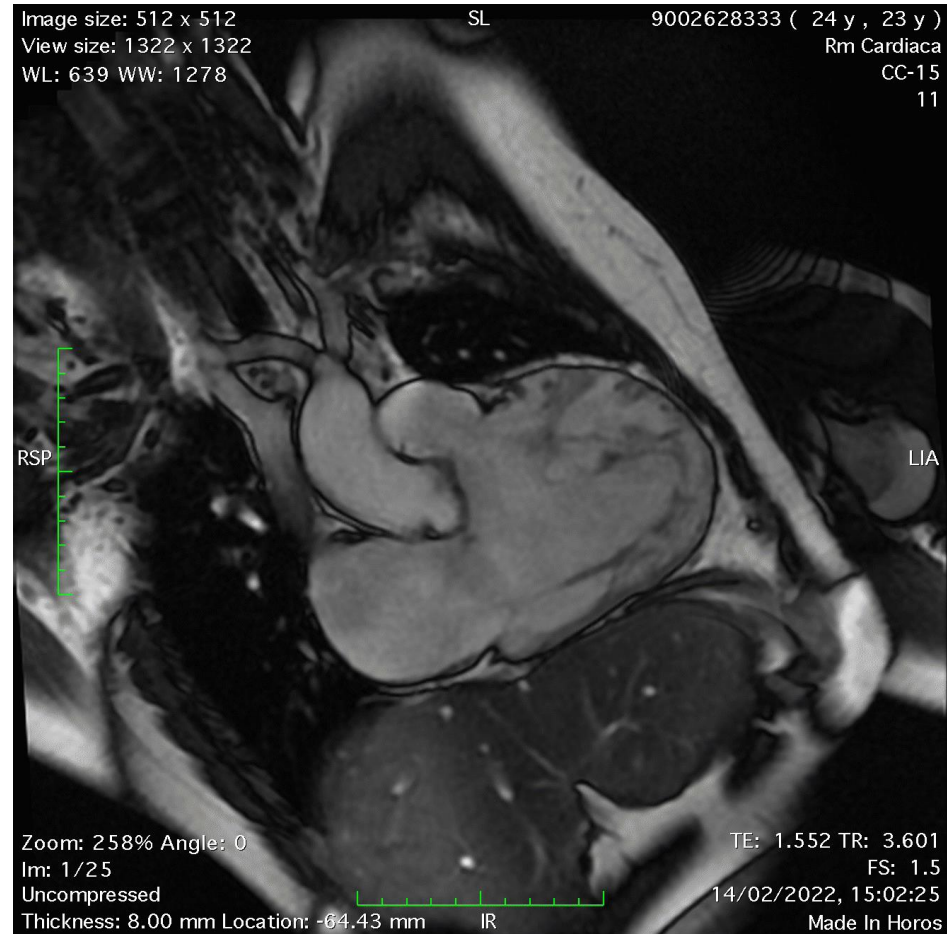EDVI 229 ml/m² (v.n. 68-114)

EDSV 121 ml/m² (v.n. 21-50)

FE 48%

FR polmonare 42%

Atrio dx area 31 cm²



VSX

EDVI 115 ml/m² (v.n. 68-103)

EDSI 52 ml/m² (v.n. 19-41)

FE 54%

Image size: 512 x 512
View size: 1322 x 1322
WL: 692 WW: 1384

SAL

9002628333 (24 y , 23 y)

Rm Cardiaca

CC-12

10

AI

PS

Zoom: 258% Angle: 0

Im: 1/450

Uncompressed

Thickness: 8.00 mm Location: -36.23 mm

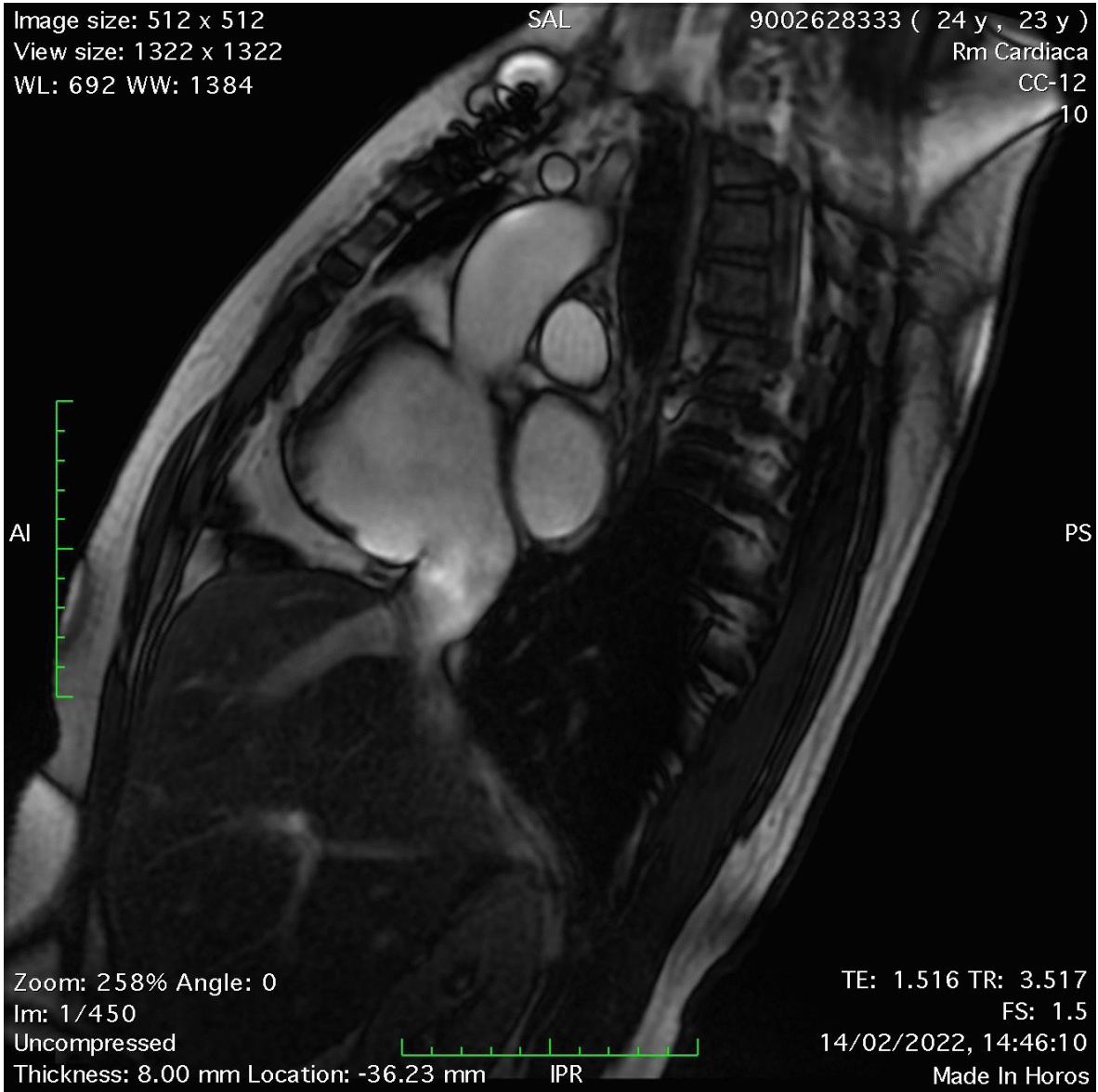
IPR

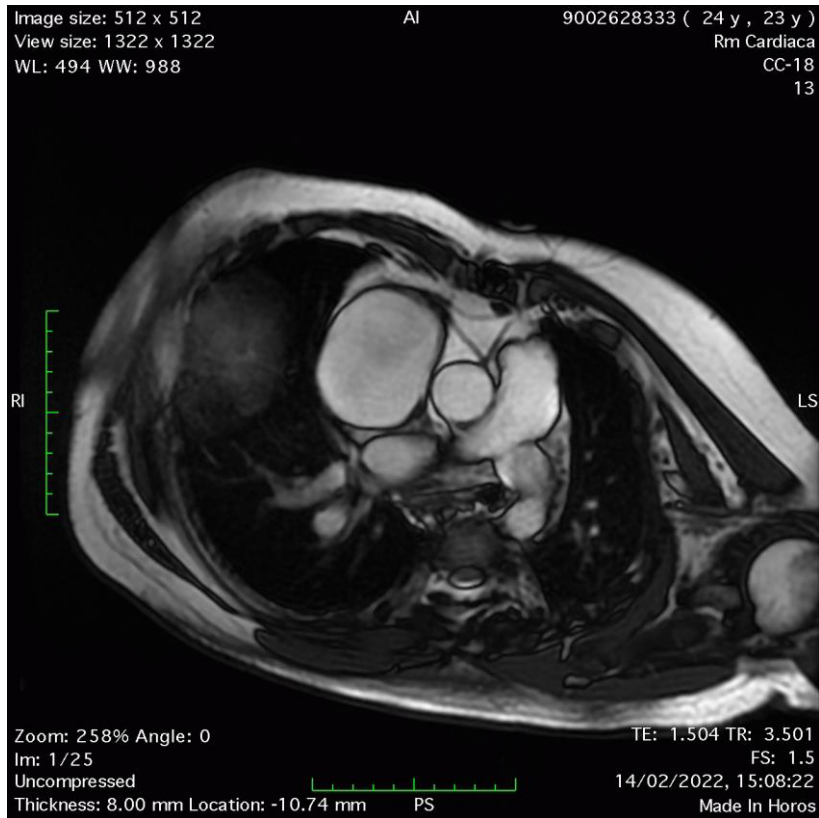
TE: 1.516 TR: 3.517

FS: 1.5

14/02/2022, 14:46:10

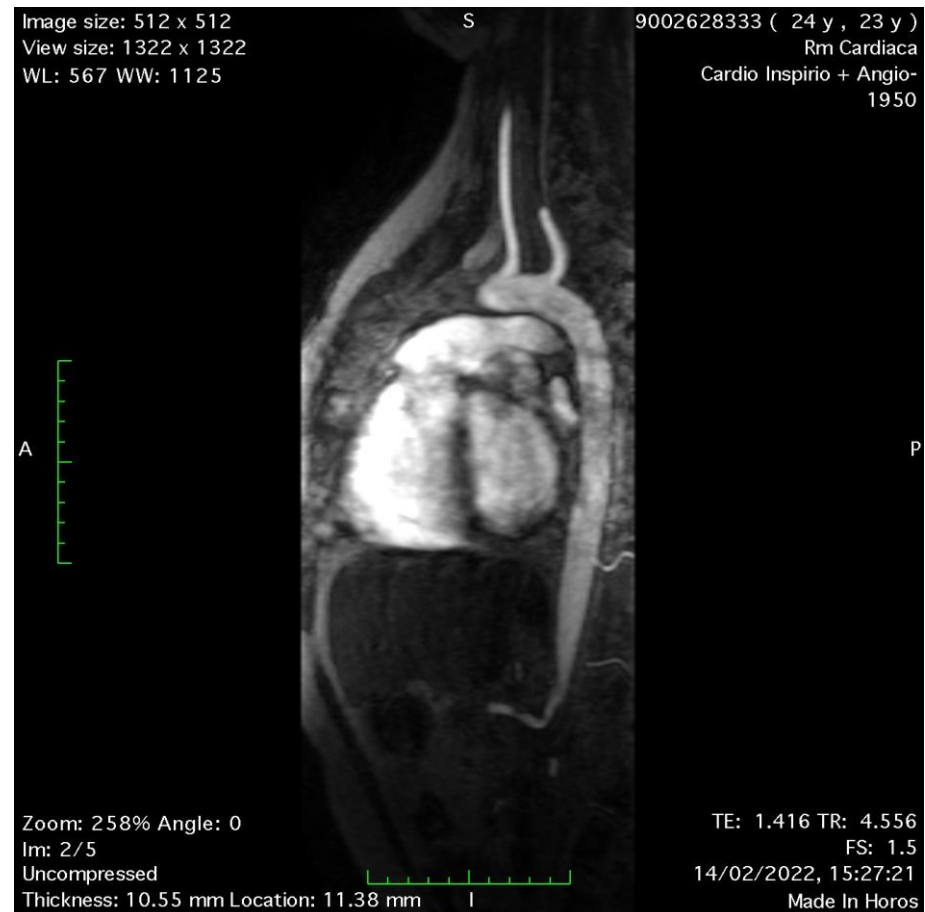
Made In Horos





Dilatazione del tronco (30X35 mm) e
dei rami

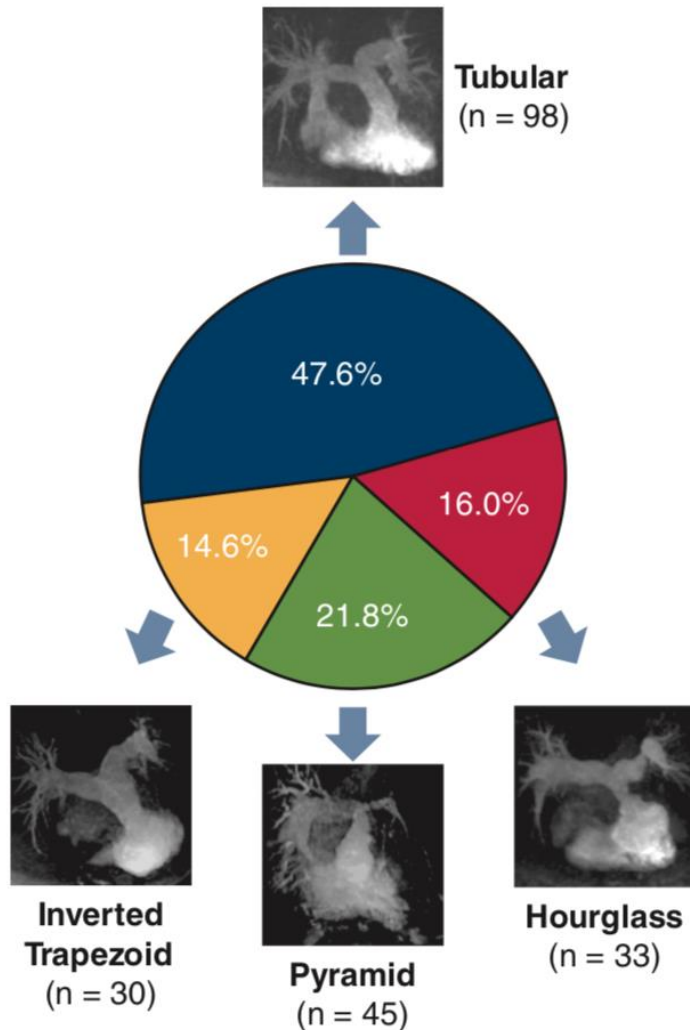
No MAPCAS residui



Indications for pulmonary valve replacement in current guidelines

Recommendations	Class ^a	Level ^b	
PVRep is recommended in symptomatic patients with severe PR ^c and/or at least moderate RVOTO. ^d	I	C	DECREASING RV VOLUMES REDUCING TR
In patients with no native outflow tract, ^e catheter intervention (TPVI) should be preferred if anatomically feasible.	I	C	DECREASING QRS DURATION INCREASING LV EF
PVRep should be considered in asymptomatic patients with severe PR and/or RVOTO when one of the following criteria is present.			IMPROVING FUNCTIONAL STATUS
<ul style="list-style-type: none"> ● Decrease in objective exercise capacity. ● Progressive RV dilation to RVEsVi ≥ 80 mL/m², and/or RVEDVi ≥ 160 mL/m² ^f, and/or progression of TR to at least moderate. ● Progressive RV systolic dysfunction. ● RVOTO with RVSP >80 mmHg. 	IIa	C	NO IMPROVEMENT IN SURVIVAL or REDUCTION OF ARRHYTHMIA BURDEN!!!

Outflow tract geometries are associated with adverse outcome indicators in repaired tetralogy of Fallot

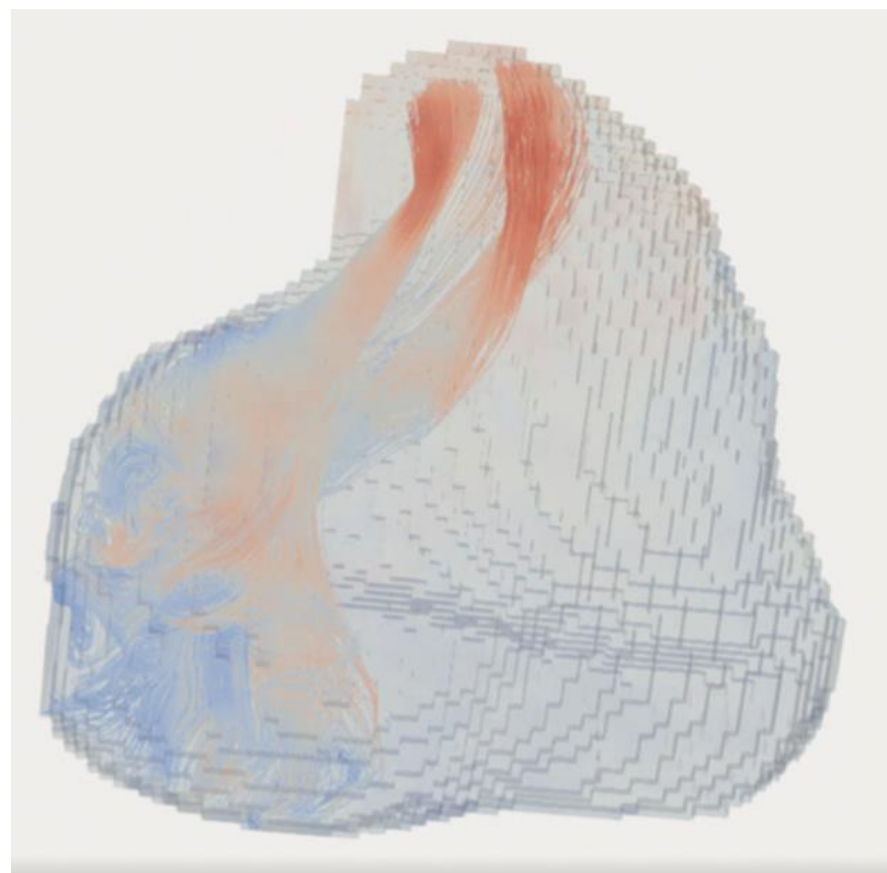
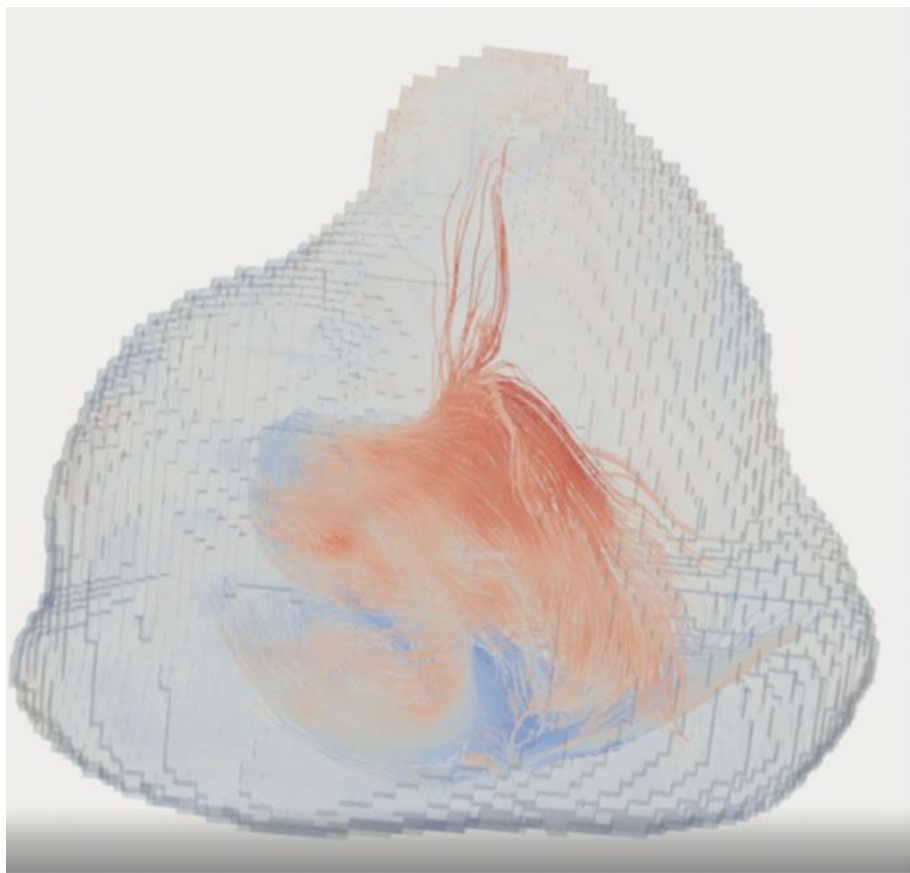


Pyramid-shaped RVOT has the largest RV EDVI and pulmonary valve annulus diameter

Inverted trapezoid-shaped RVOT has the smallest RV EDVI, pulmonary valve annulus diameter and shortest QRS duration

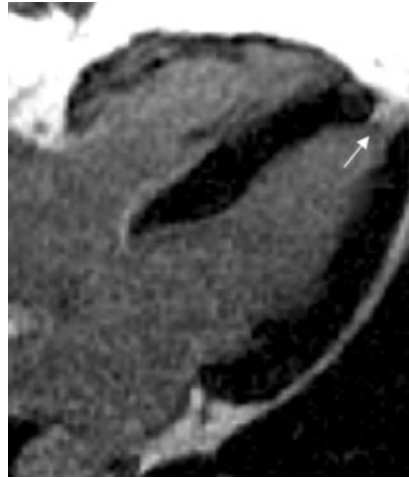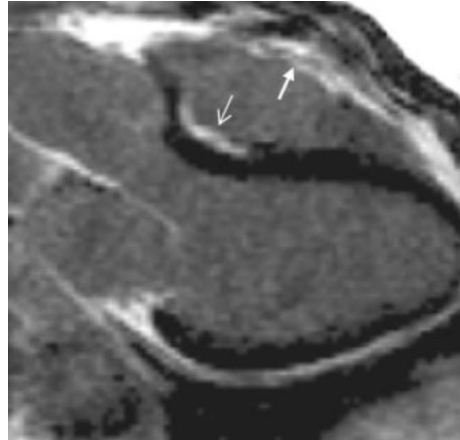
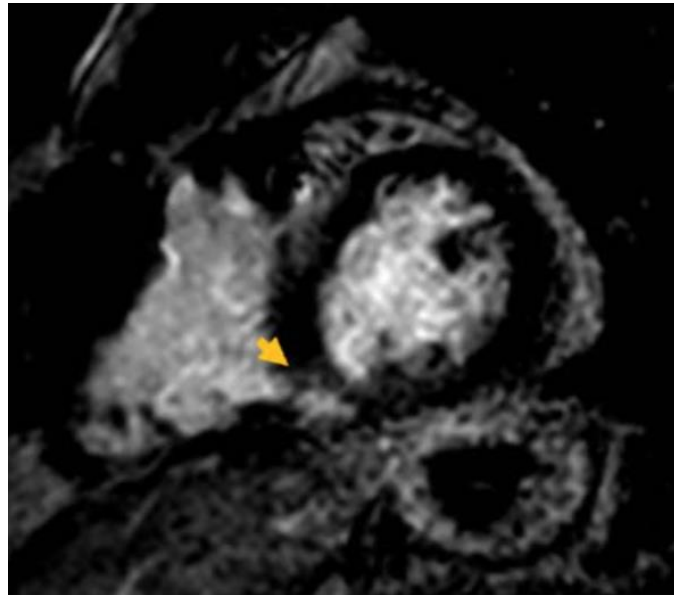
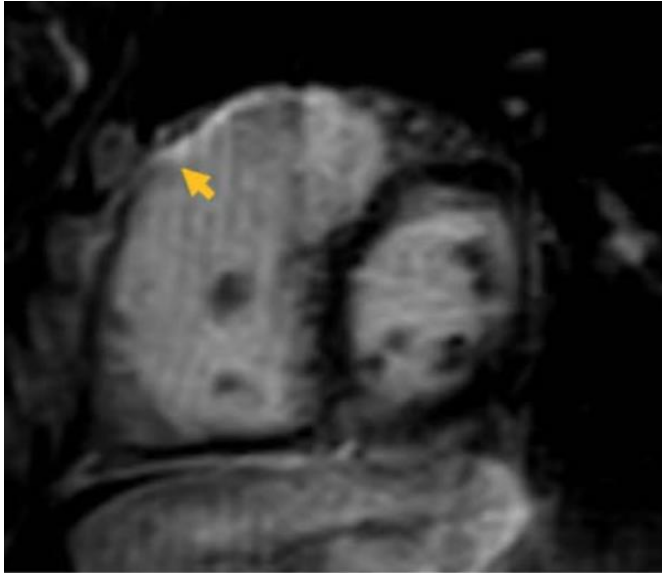
Less extensive incision and pathing of the RVOT resulting in the better preservation of the RVOT mechanics

4D Flow MRI



Ventricular Fibrosis Suggested by Cardiovascular Magnetic Resonance in Adults With Repaired Tetralogy of Fallot and Its Relationship to Adverse Markers of Clinical Outcome

Sonya V. Babu-Narayan, BSc, MRCP; Philip J. Kilner, MD, PhD; Wei Li, MD, PhD;
James C. Moon, MRCP; Omer Goktekin, MD; Periklis A. Davlouros, MD; Mohammed Khan, MPH;
Siew Yen Ho, PhD, FRCPath; Dudley J. Pennell, MD, FRCP; Michael A. Gatzoulis, MD, PhD



RV and LV LGE

ventricular dysfunction

ventricular arrhythmia

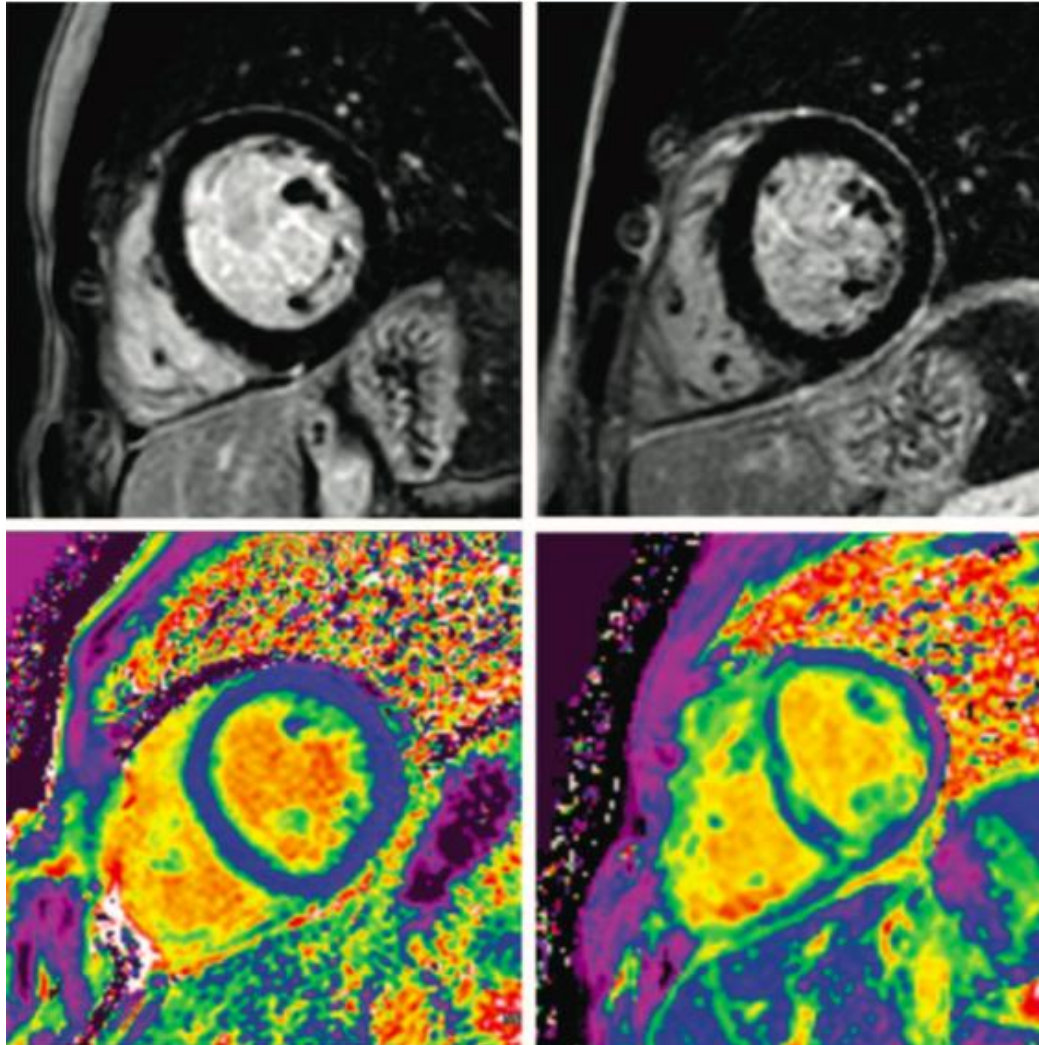
exercise intolerance

neurohormonal activation

OLDER
HISTORY OF REDO SURGERY

T1 mapping

T1-mapping techniques allow quantification of ECV (extracellular volume fraction) and diffuse myocardial fibrosis



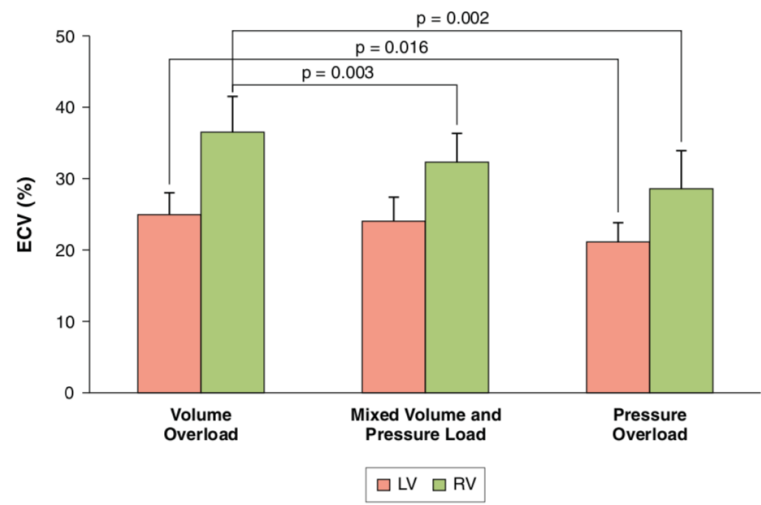
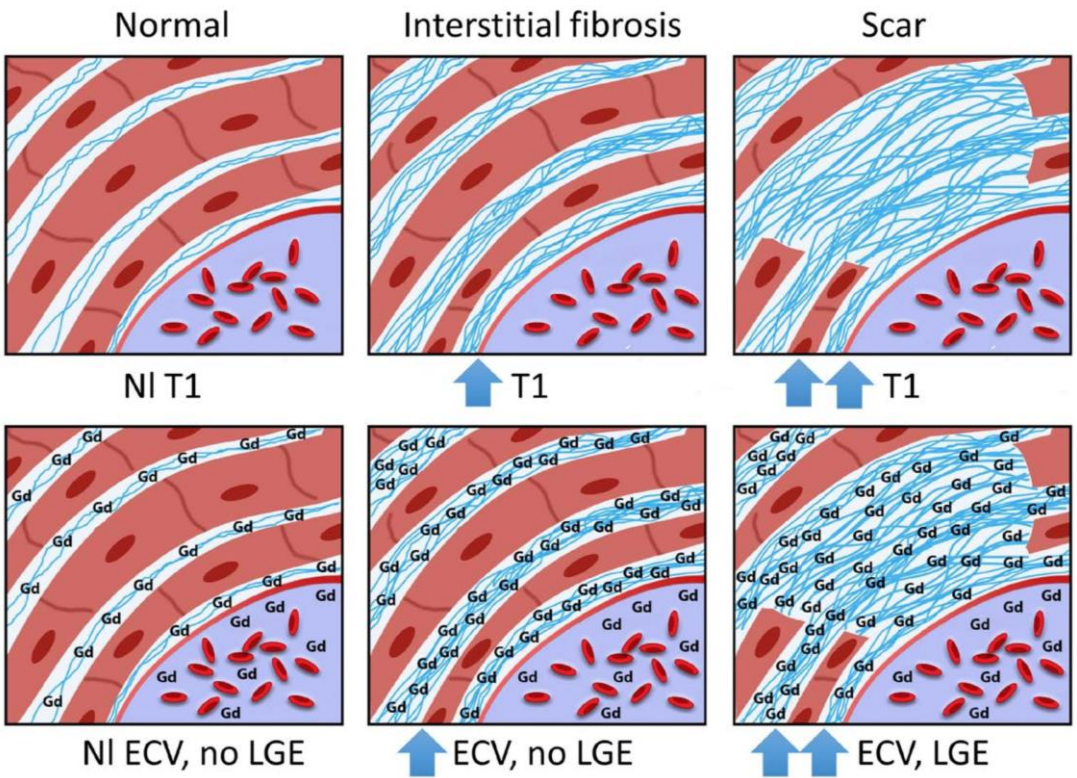
Myocardial ECV Fraction Assessed by CMR Is Associated With Type of Hemodynamic Load and Arrhythmia in Repaired Tetralogy of Fallot

Chun-An Chen, MD, PhD, Susan M. Dusenbery, MD, MS, Anne Marie Valente, MD, Andrew J. Powell, MD, Tal Geva, MD

Positive linear relationship between LV and RV ECV

Greater ECV associated with RV volume overload, lower RV outflow gradient and female gender

LV ECV independently associated with arrhythmia

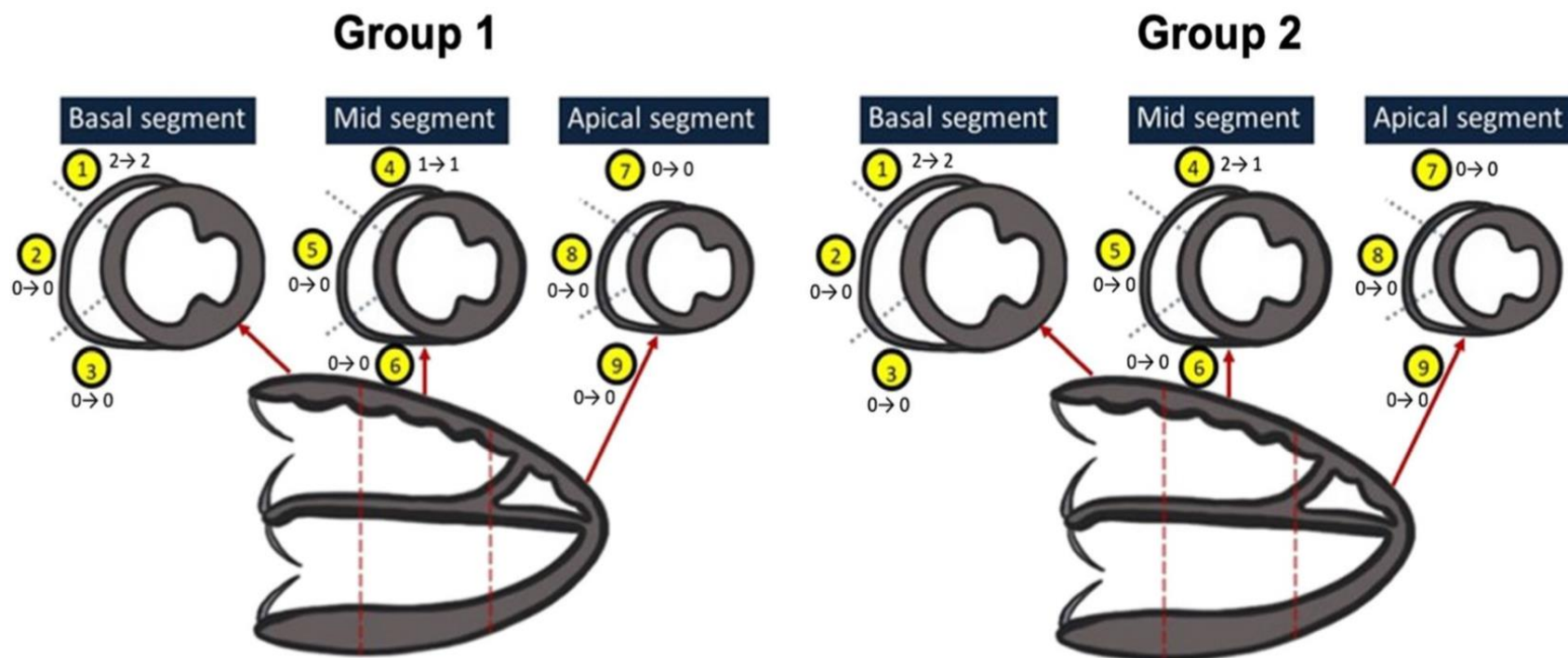


Longitudinal changes in extent of late gadolinium enhancement in repaired Tetralogy of Fallot: a retrospective analysis of serial CMRs

Kwannapas Saengsin¹, Minmin Lu¹, Lynn Sleeper^{1,2}, Tal Geva^{1,2} and Ashwin Prakash^{1,2*}

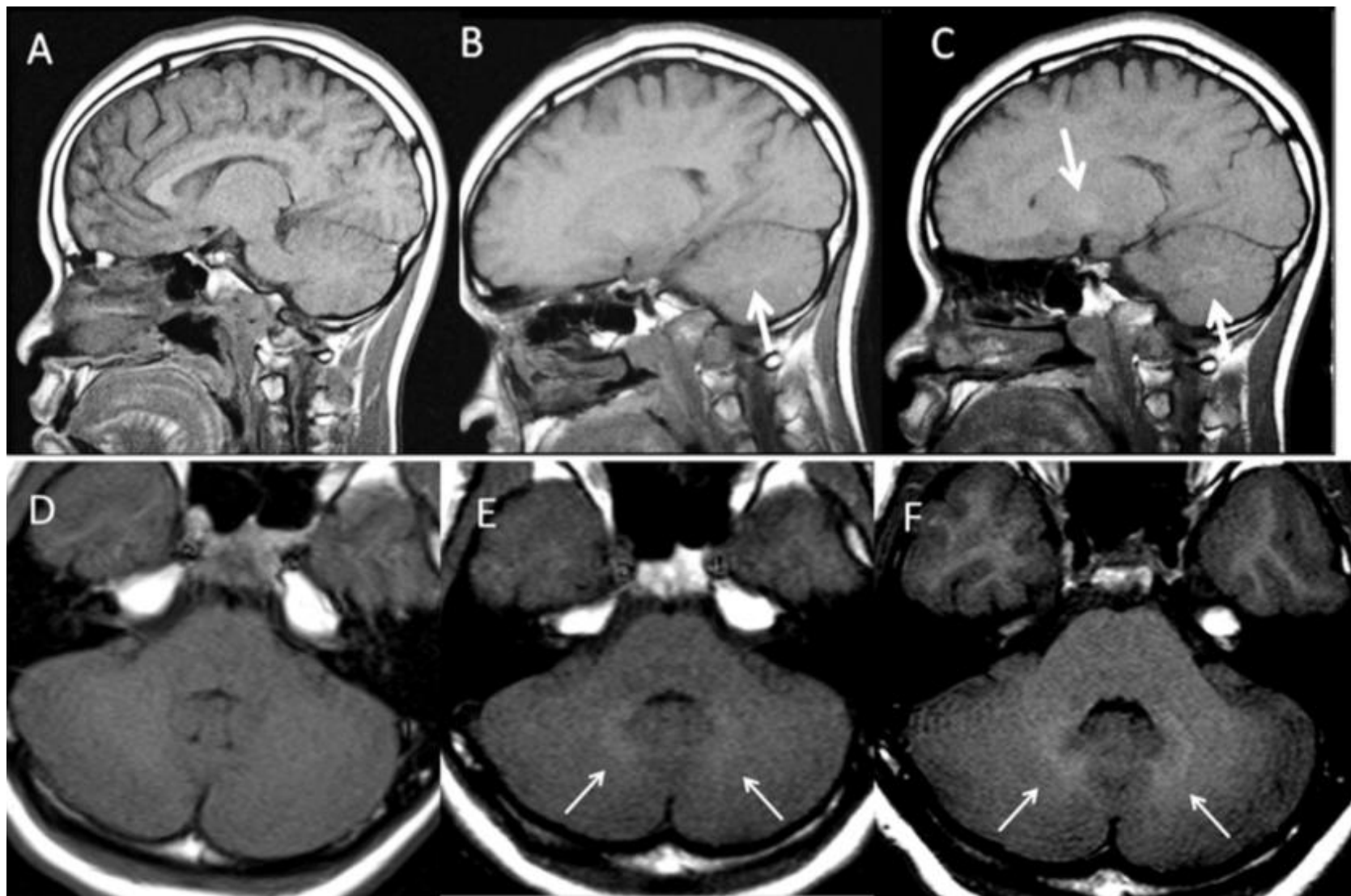
RV LGE present in all patients on the first CMR

No significant progression in the extent was seen on intermediate term follow up (5 year)



Progressive increase of T1 signal intensity in the dentate nucleus and globus pallidus on unenhanced T1-weighted MR images in the pediatric brain exposed to multiple doses of gadolinium contrast

Donna R. Roberts^{a,b,*}, Kenton R. Holden^{b,c}



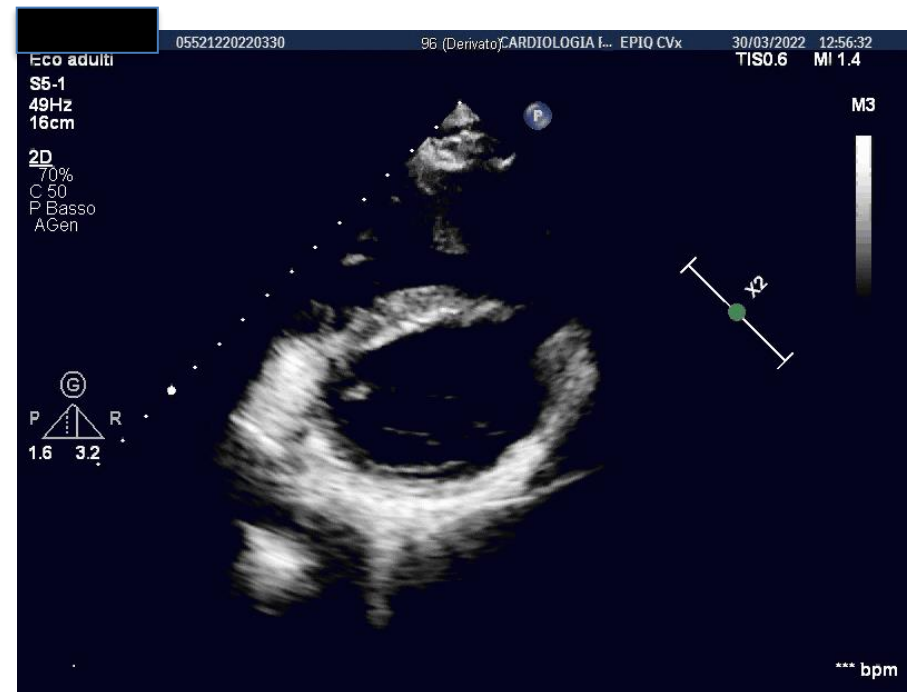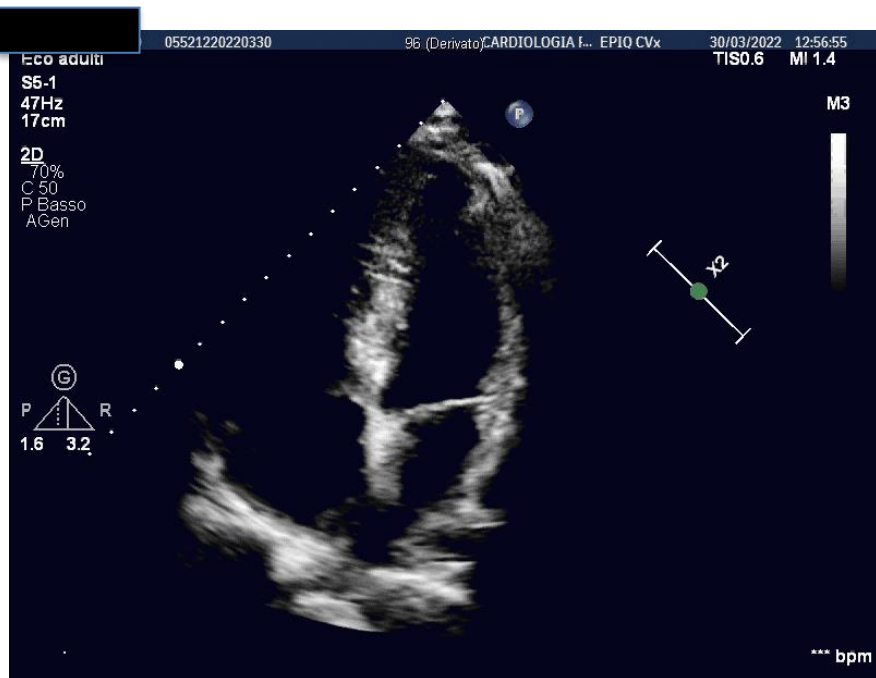
BERNARDO 34 aa

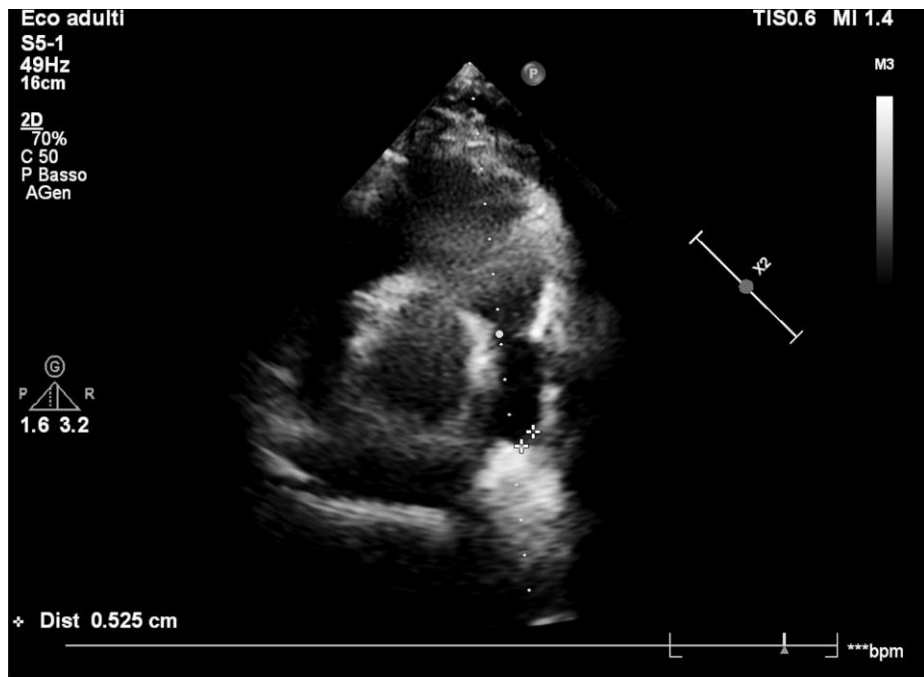
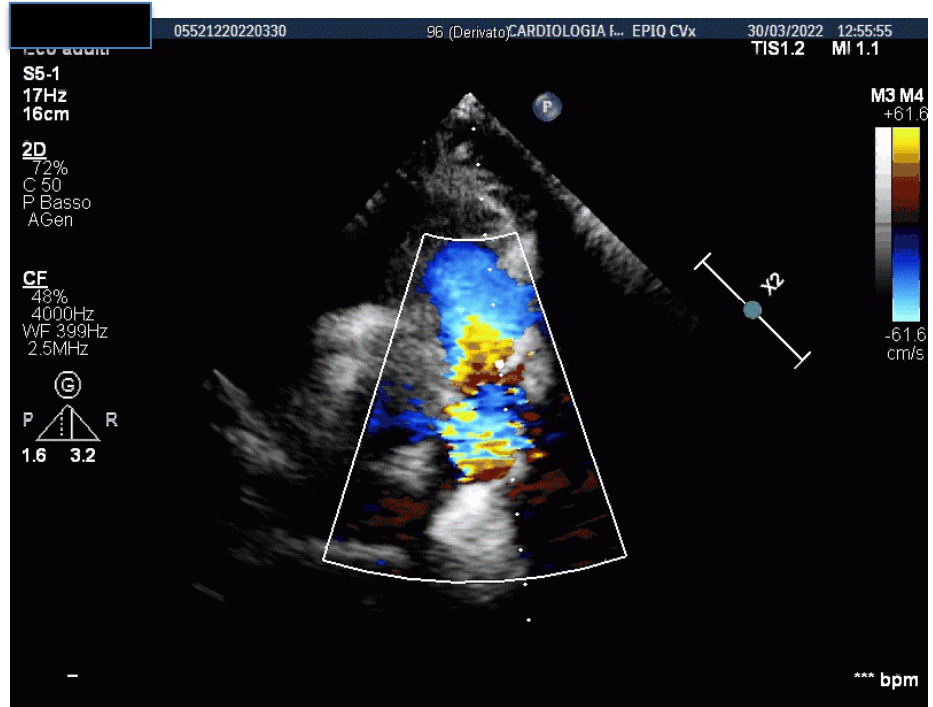
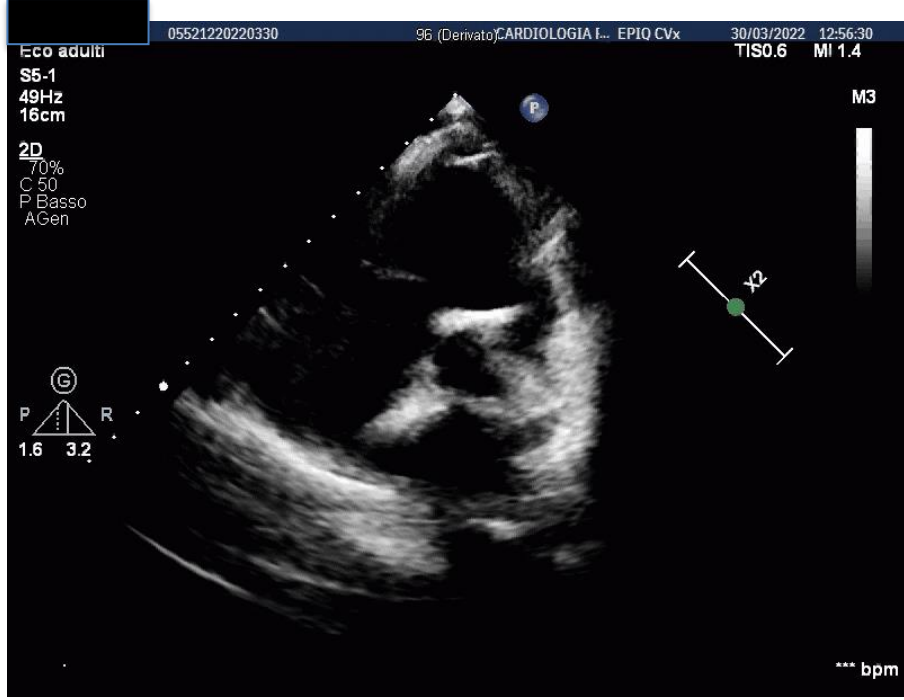23/5/1990

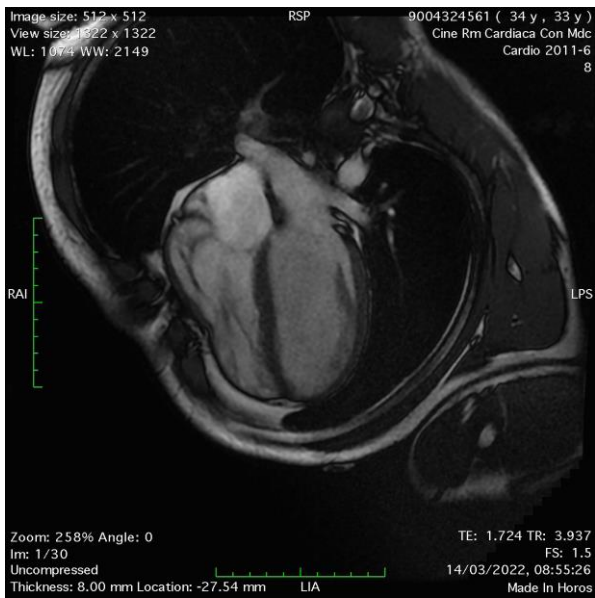
TOF s/p a intervento CCH di chiusura DIV e patch transanulare
fino all'origine del ramo polmonare sx

2022

Visita cardiologica presso l'ospedale di Ivrea







VDX

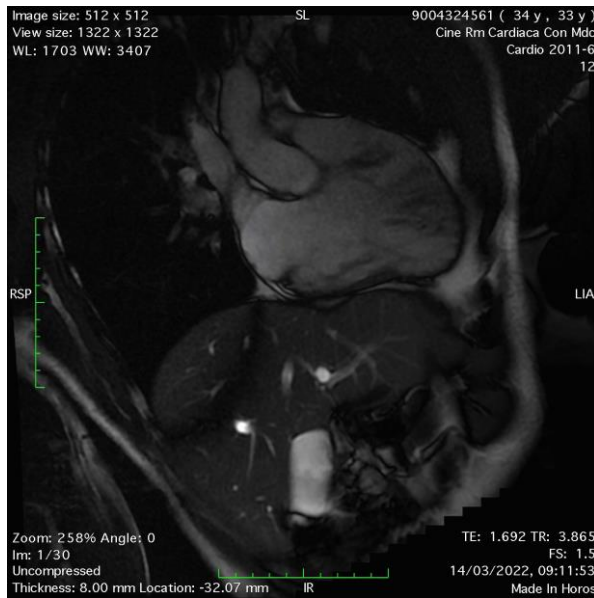EDVI 150 ml/m² (v.n. 68-114)

EDSVI 80 ml/m² (v.n. 21-50)

FE 47%

FR polmonare 37%

Atrio dx 21 cm²

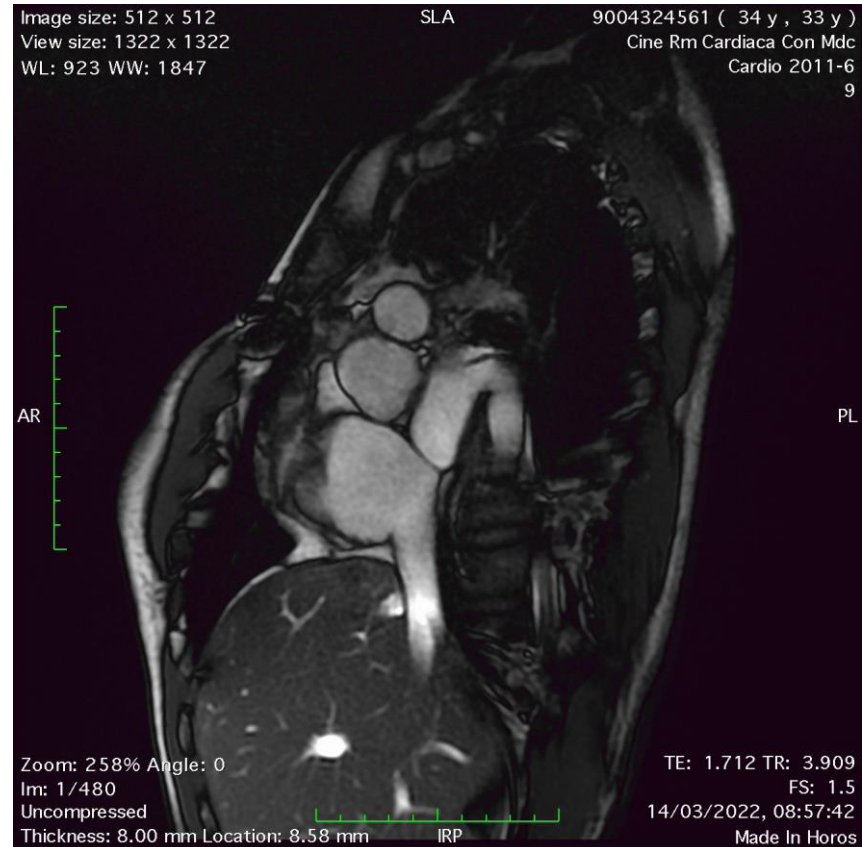


VSX

EDVI 104 ml/m²

EDSVI 50 ml/m²

FE 52%

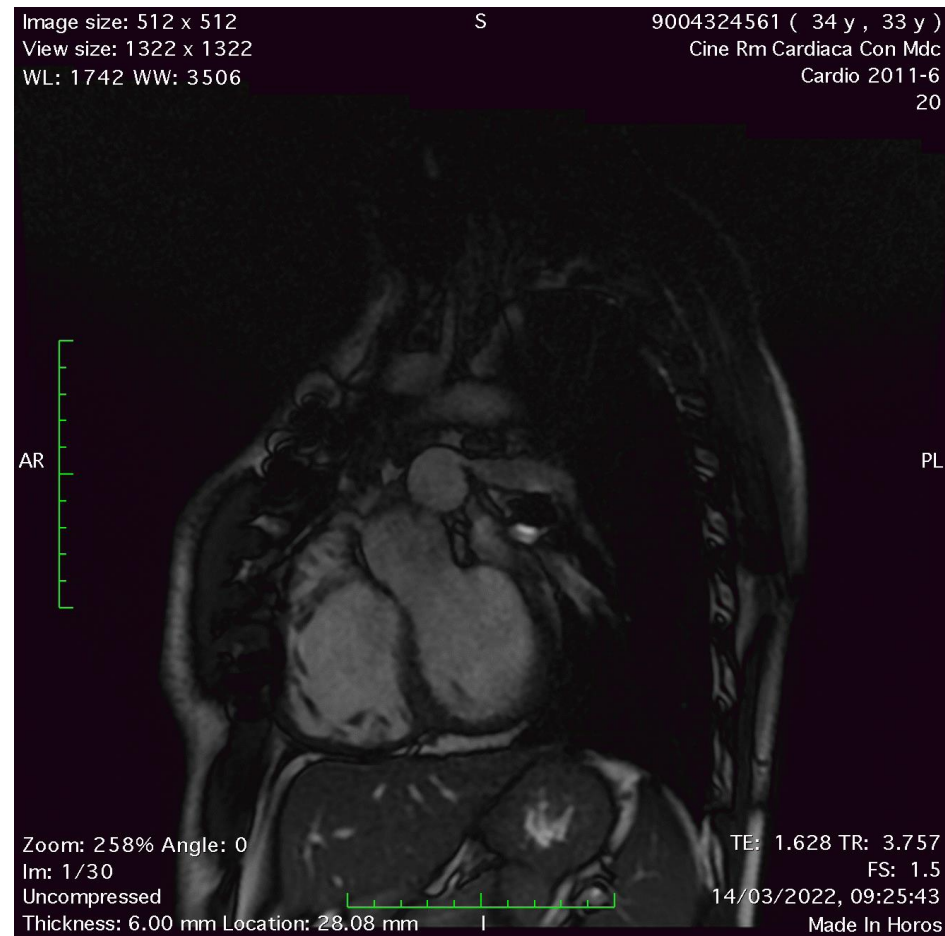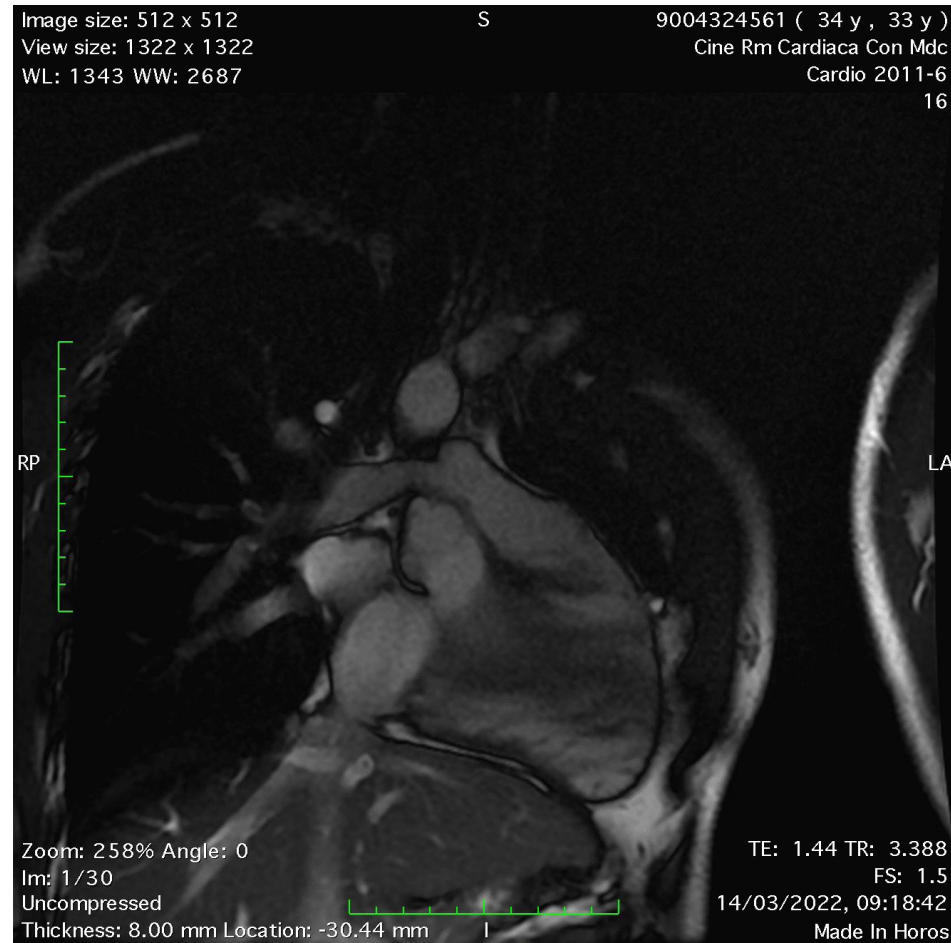


FLUSSO SBILANCIATO NEI RAMI POLMONARI

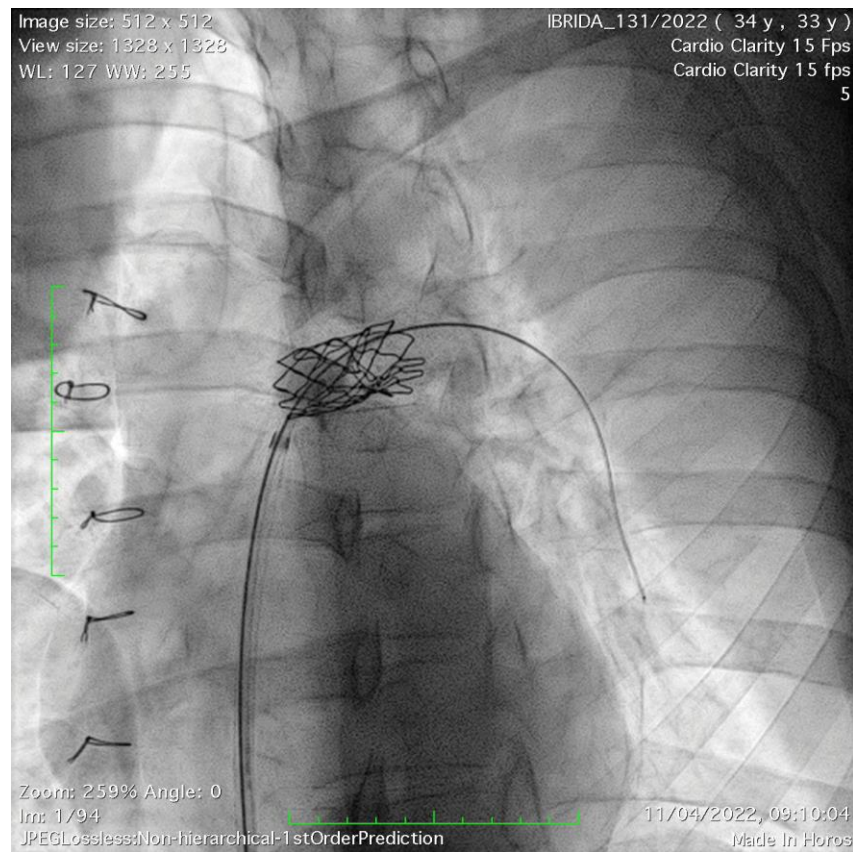
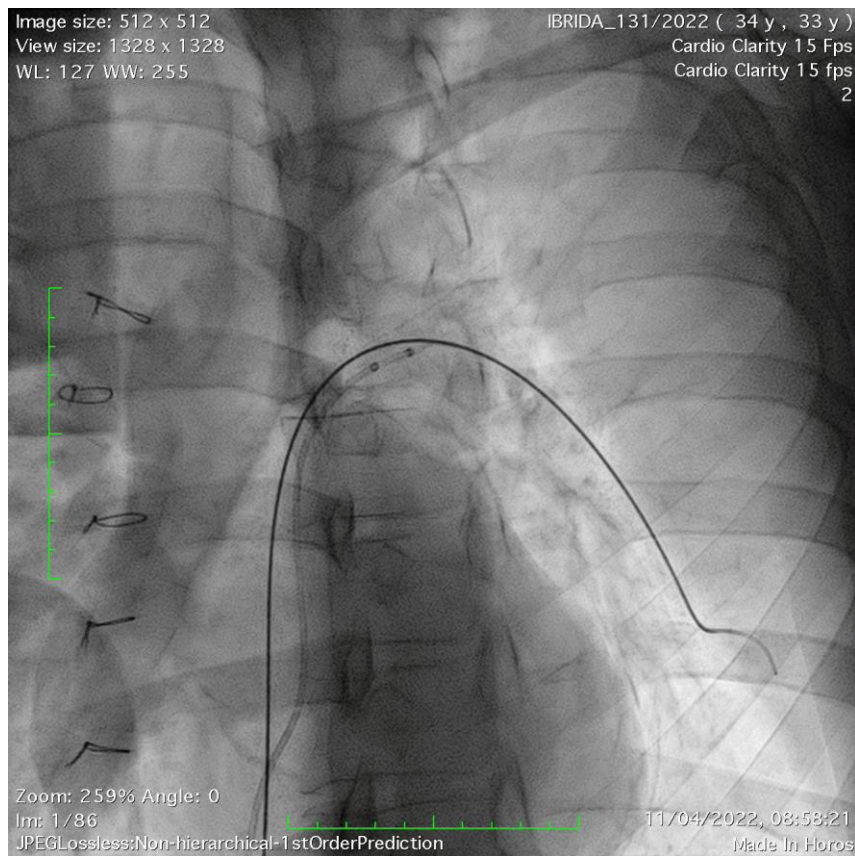
Peggiora il rapporto V/Q dei polmoni e riduce la capacità di esercizio

80%

20%

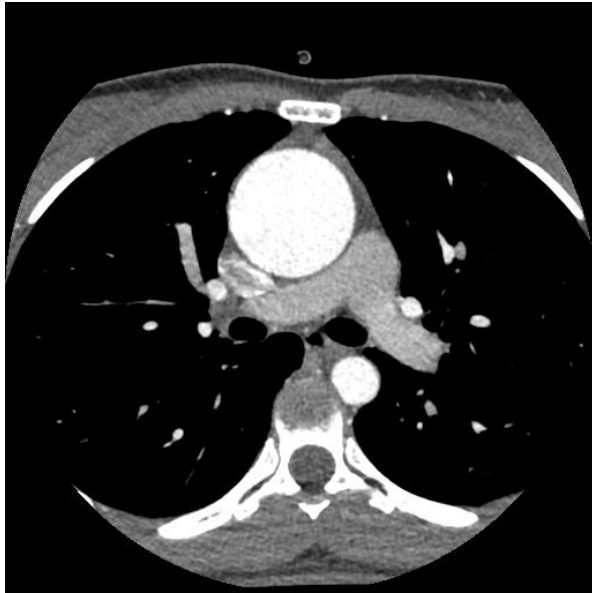


STENTING DELL'OSTIO DI LPA CON CP 34 MM MONTATO SU BIB 14X30



Aortic disease and interventions in adults with tetralogy of Fallot

Alexander C Egbe,¹ William R Miranda,¹ Naser M Ammash,¹ Nandan S Anavekar,¹ Venkata R Missula,¹ Srikanth Kothapalli,¹ Arooj R Khan,¹ Sameh M Said,² Heidi M Connolly¹



453 adult patients with TOF

51% aortic root dilatation

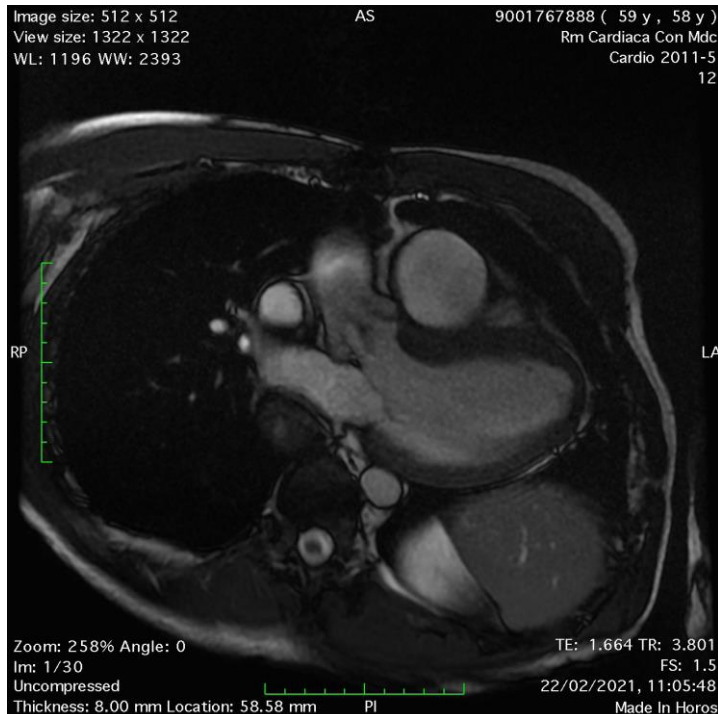
69% ascending aorta dilatation

Aortic regurgitation 28% → 3% moderate

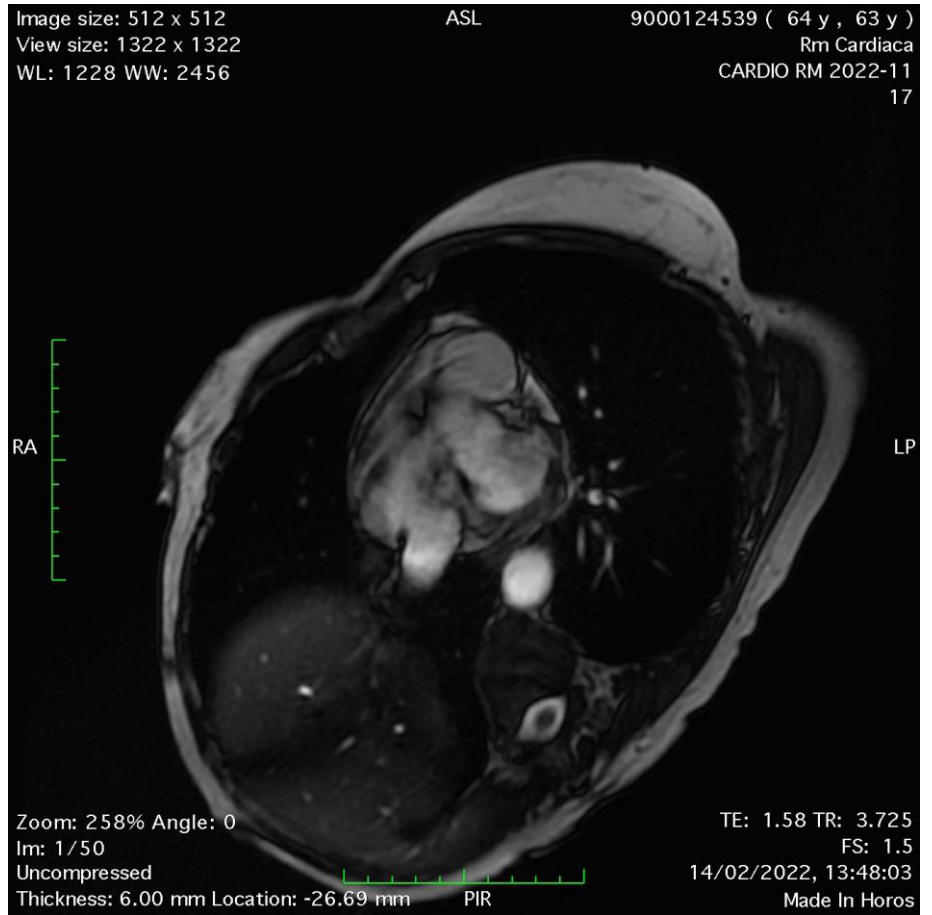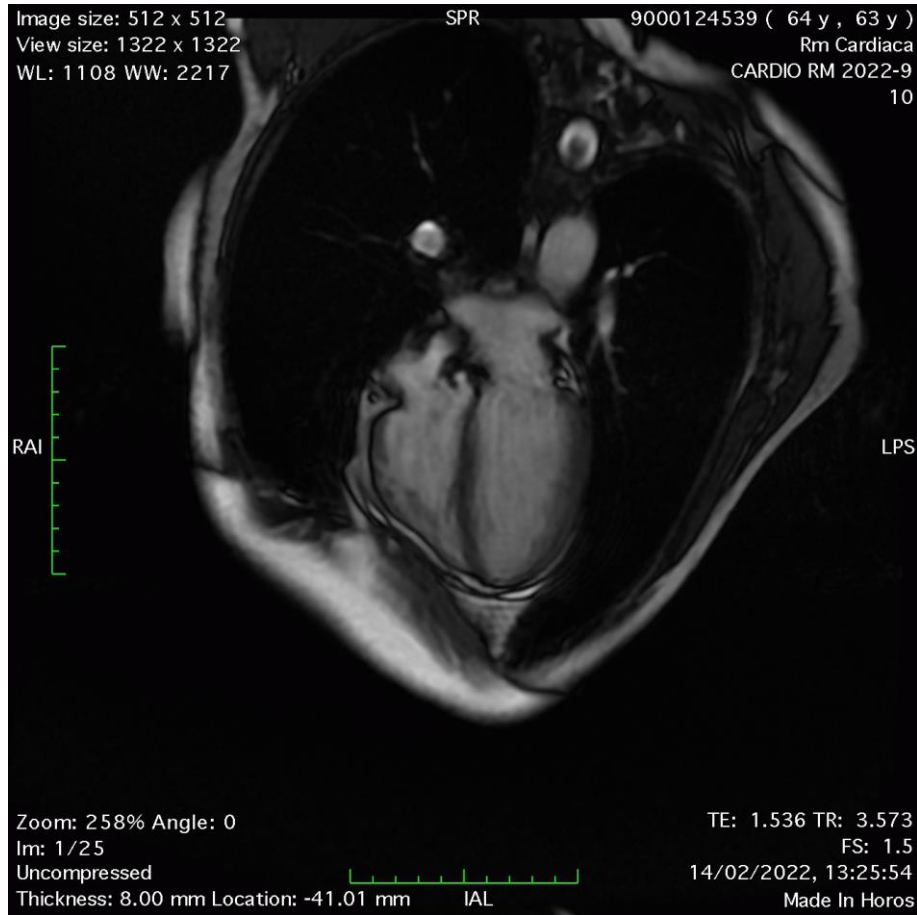
91% did not show progressive aortic dilatation during follow up (8y)

No patient had aortic dissection (50-56 mm did not undergo aorta surgery)

Almost all the cases of dissection at aortic dimensions of 70 mm



DIV RESIDUO 6-10%



Carlo 60 aa

All'età di 13: intervento per Tetralogia di Fallot

Nessun follow up negli anni

Fattori di rischio per CAD: Iperteso, dislipidemico e fumatore

IRC stadio III su base nefroangiosclerotica

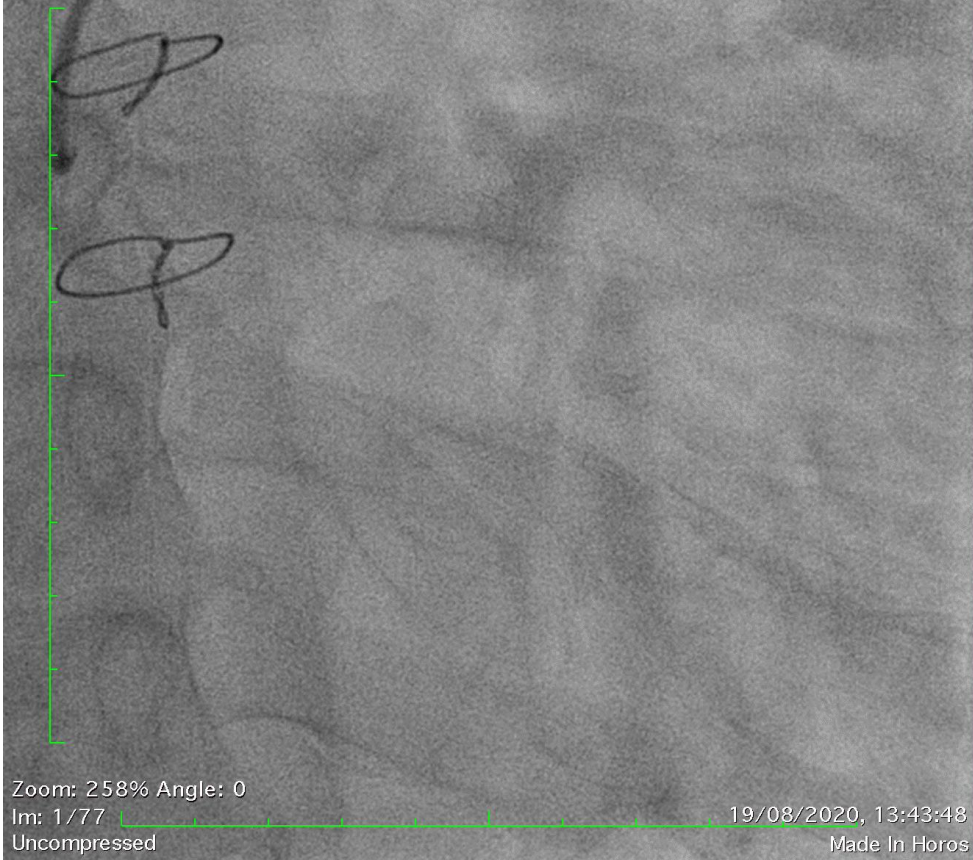8/2020

Ospedale Molinette

Ricovero per NSTEMI

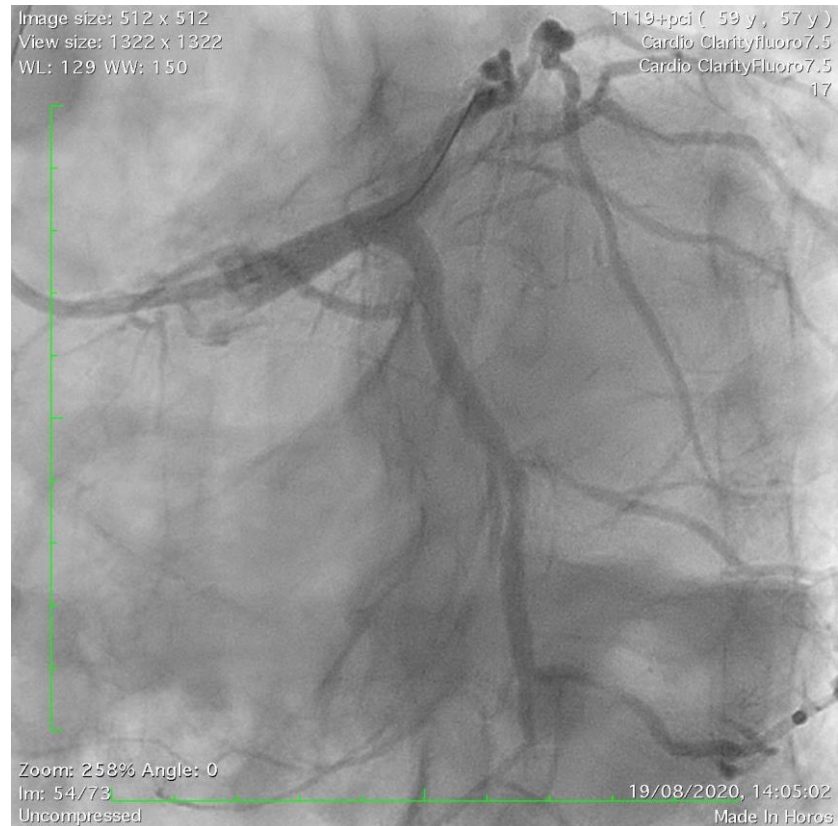Image size: 512 x 512
View size: 1322 x 1322
WL: 128 WW: 179

1119+pci (59 y , 57 y)
Cardio ClarityFluoro7.5
Cardio ClarityFluoro7.5
4



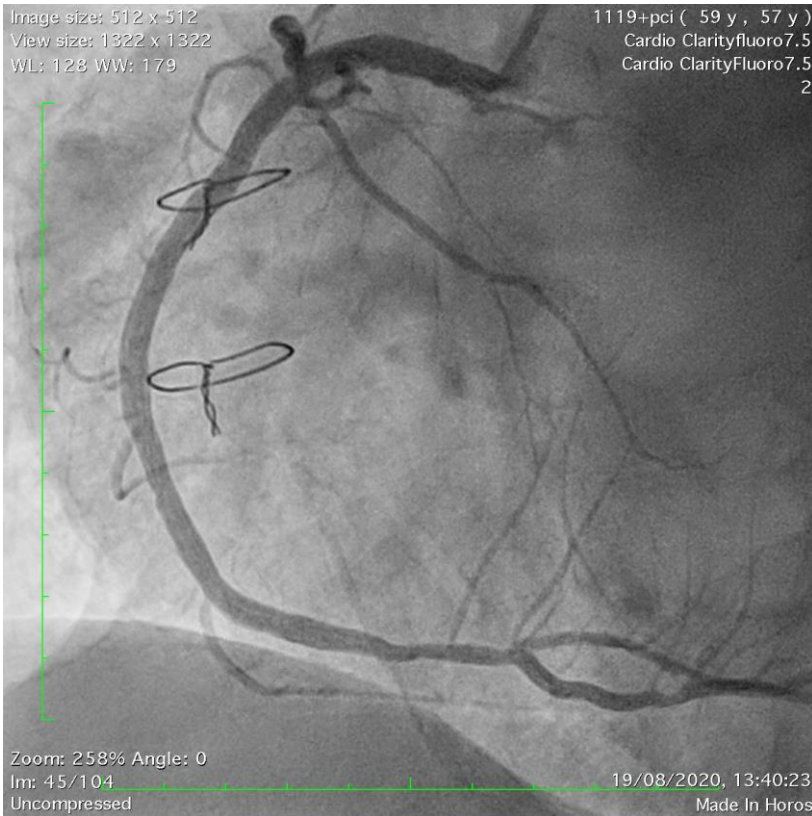
PCI+DES su Cx III

Residua stenosi subcritica di IVA II e CDX



12/2020 Ecocardio

Vsx DTD 53 mm EDVI 106 ml/m²,
ipertrofia concentrica (SIV 15 mm)
FE 42%
ipocinesia infero-laterale e antero
laterale
disfunzione diastolica II
IAO moderata



Vdx dilatato 47 mm TAPSE 24 mm
FAC 25% Paps 25 mmHg
tronco e rami polmonari dilatati

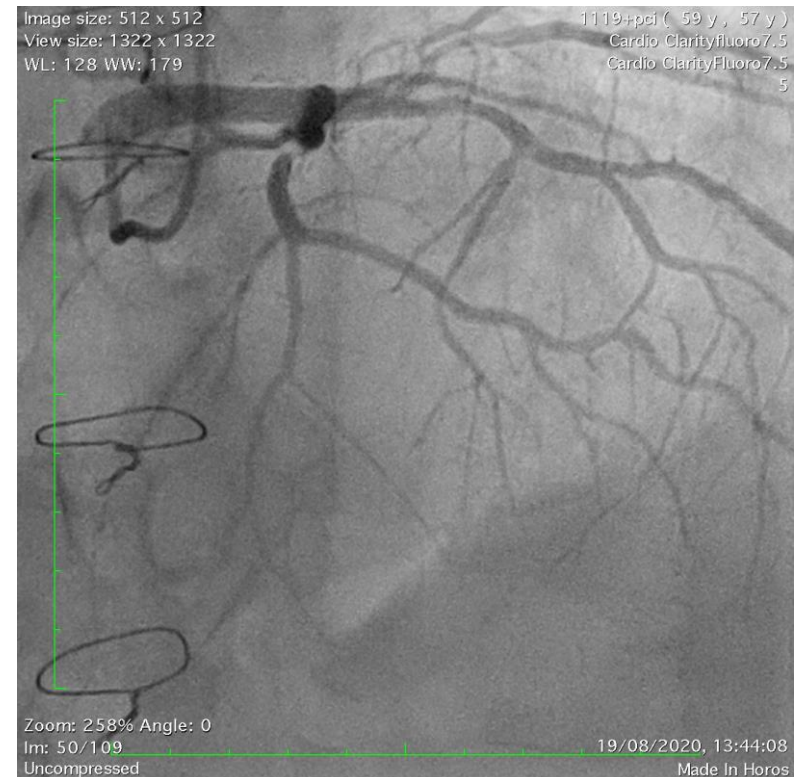
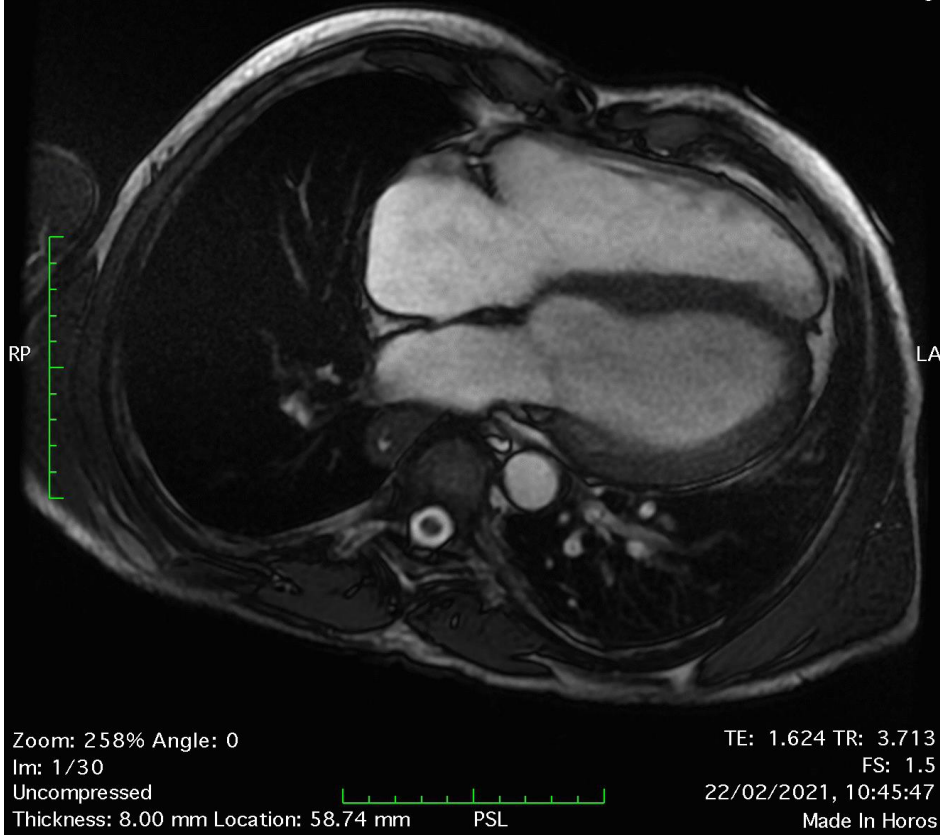


Image size: 512 x 512
View size: 1322 x 1322
WL: 911 WW: 1823

AIR
9001767888 (59 y , 58 y)
Rm Cardiaca Con Mdc
Cardio 2011-5
9

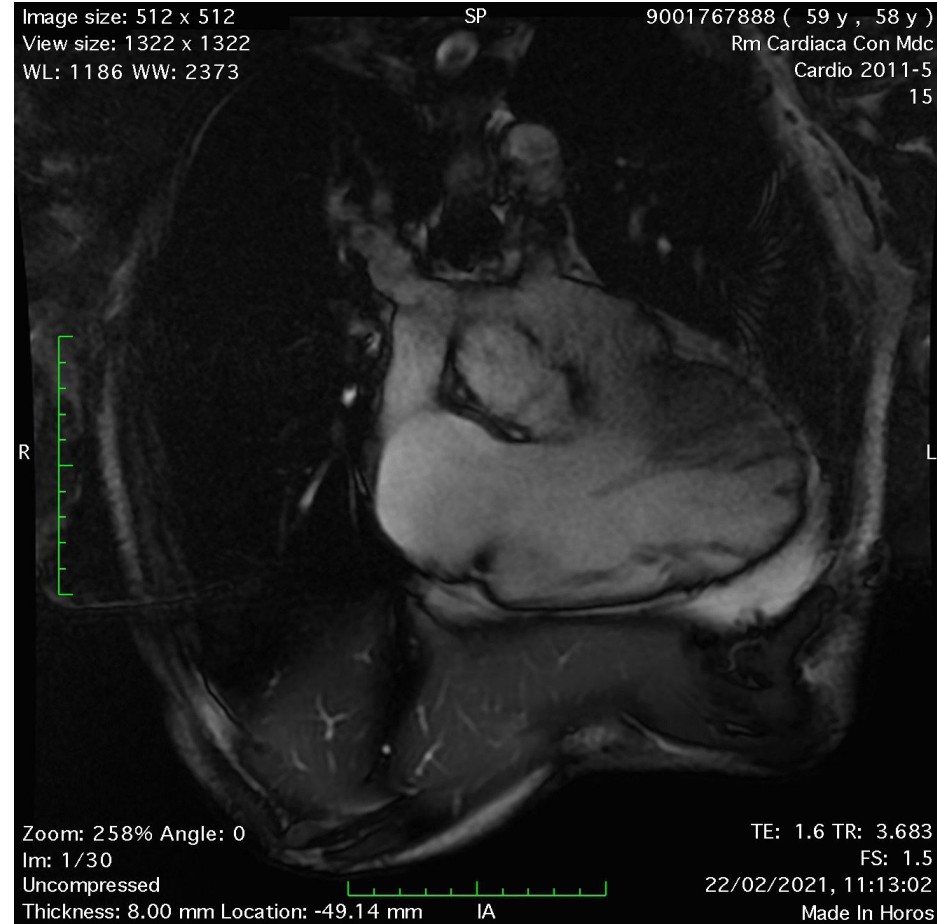


VDX

EDVI 205 ml/m² (v.n. 59-105)
EDSVI 114 ml/m² (v.n. 13-42)
FE 45%
Atrio dx 34 cm²

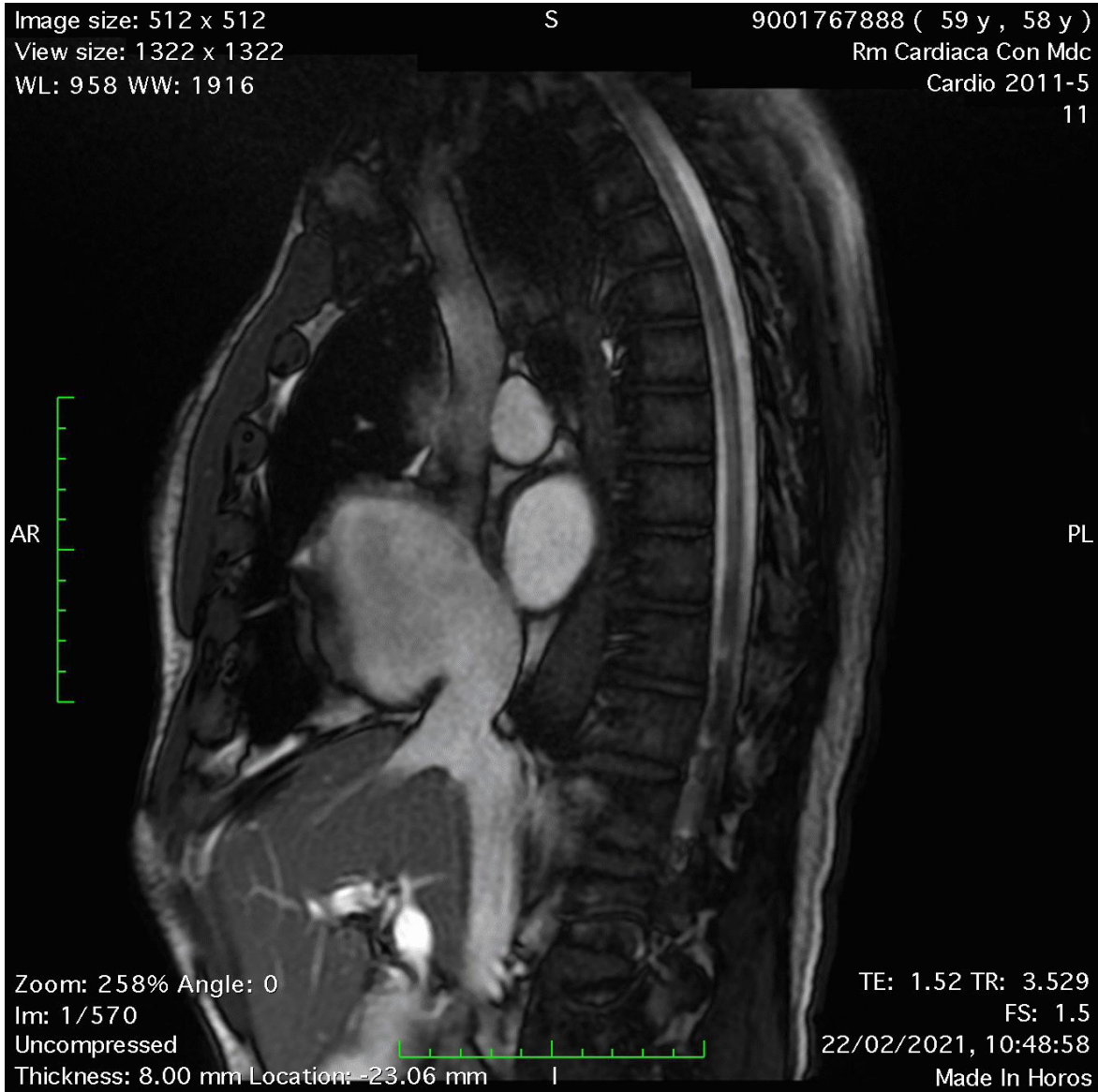
Image size: 512 x 512
View size: 1322 x 1322
WL: 1186 WW: 2373

SP
9001767888 (59 y , 58 y)
Rm Cardiaca Con Mdc
Cardio 2011-5
15



Ampio patch infundibolare con
anastomosi distale alla
biforcazione polmonare

FR polmonare 40%



Vsx

EDVI 129 ml/m² (v.n. 62-97)

EDSVI 61 ml/m² (v.n. 15-37)

FE 52%

Atrio sx 24 cm²

IAO moderata FR 25%

Ipocinesia parete infero-laterale media e antero laterale mediobasale

NO LGE GFR <30!!!!

The Forgotten Ventricle?

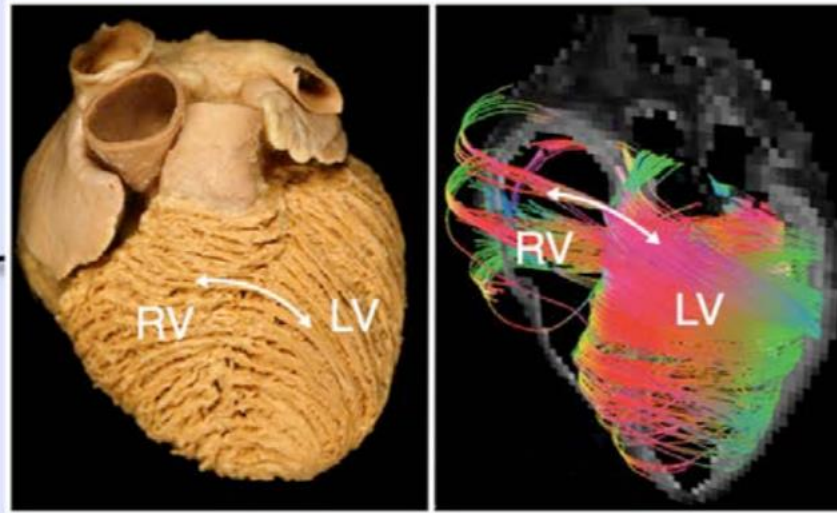
The Left Ventricle in Right-Sided Congenital Heart Disease

Justin T. Tretter, MD; Andrew N. Redington, MD

VENTRICULAR-VENTRICULAR INTERACTIONS

Mechanical Coupling

- shared aggregated cardiomyocytes
- shared interventricular septum
- shared pericardial space
- circuit in series




Neurohormonal Coupling

- myocardial fibrogenesis

Electromechanical Coupling

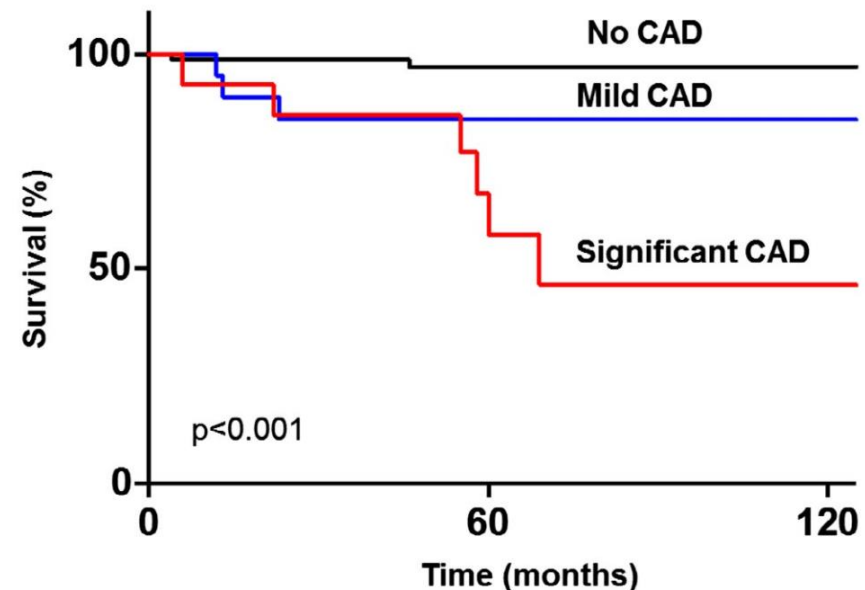
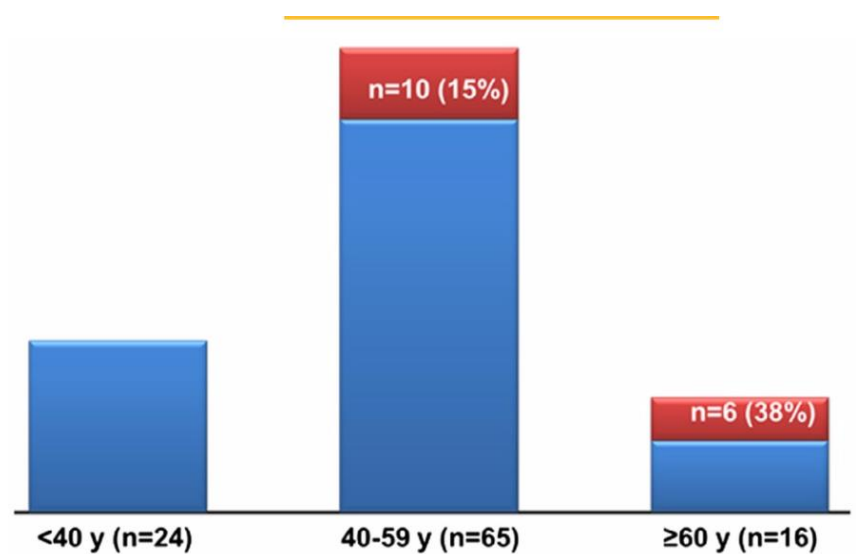
Coronary artery disease in adults with tetralogy of Fallot

Alexander C. Egbe MD, MPH  | Sindhura Ananthaneni MD | Raja Jadav MD |
Srikanth Kothapalli MD | Charanjit S. Rihal MD | Muhammad Masood MD |
Mounika Angirekula MD | Maria Najam MD | Numra Bajwa MBBS |
Karim Tarek MBBS | Jessey Matthew MBBS | Heidi M. Connolly MD

Coronary angiograms were performed in 105 pz:

Preoperative evaluation for cardiac surgery (75%)

- Abnormal stress test (18%)
- Chest pain and/or dyspnea (0,7%)
- NSTEMI (3%)
- LV dysfunction (3%)





VI CORSO GUCH

**Il paziente adulto
con cardiopatia
congenita**

TORINO
03 DICEMBRE 2022
NH TORINO CENTRO

