CHIUSURA PERCUTANEA DELL'AURICOLA SINISTRA: DALLE LINEE GUIDA ALLA PRATICA CLINICA

Ruolo dell'ecografia intravascolare durante la procedura

C.Amellone

Cardiologia Osp. Maria Vittoria

ECOGRAFIA INTRACARDIACA ICE

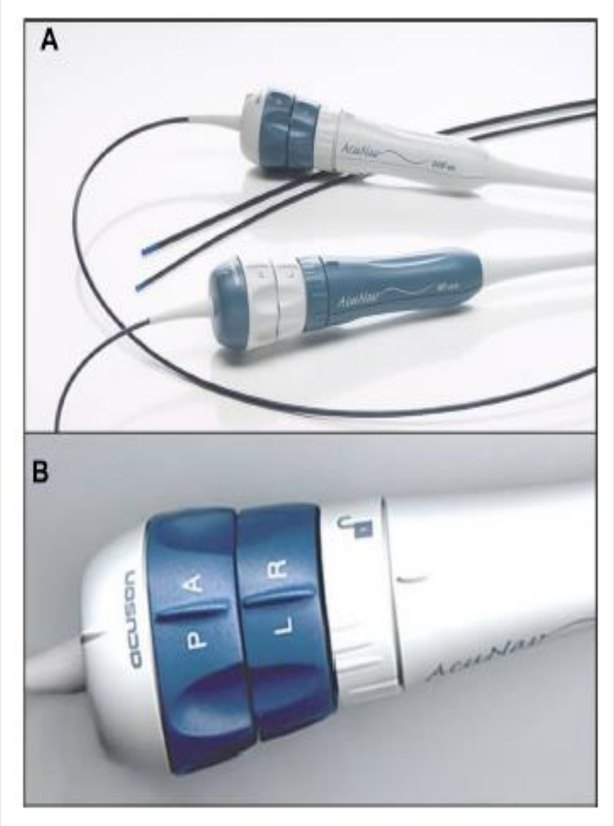

<u>Acuson Acunav</u>

Trasduttore 64 elementi
Vista 90°
Deflessioni anteroposteriore/laterale
ColorDoppler
Introduttore 8-10F

- ViewMate™ Ultrasound Console and ViewFlex™ Xtra ICE Catheter

ViewMate™ Ultrasound Console

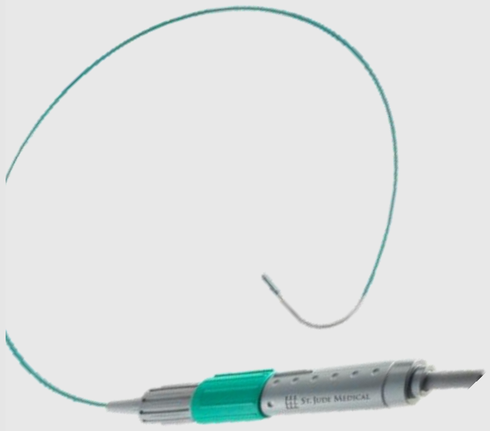



ViewFlex™ Xtra ICE Catheter

- Manipolo ergonomico
- 4 movimenti, 120°
- 64-element phased array trasduttore
- Connettore sterile
- 10 F

TECNOLOGIA ZONARE

CONVENTIONAL



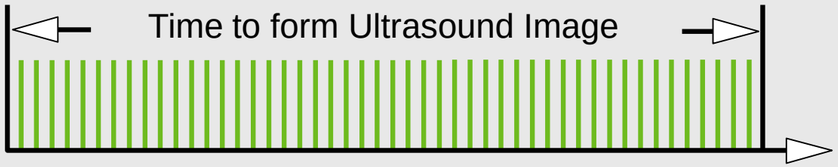

Line-by-line data acquisition

Hardware-based

Data discarded

Tradeoff between image quality and portability

ZONE SONOGRAPHY

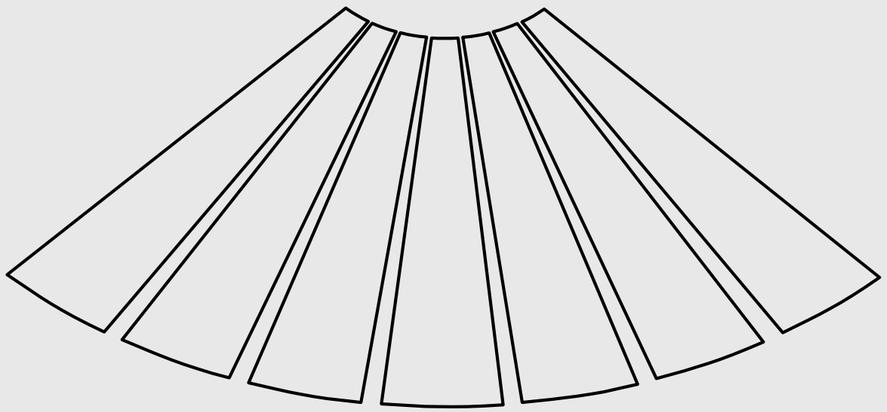

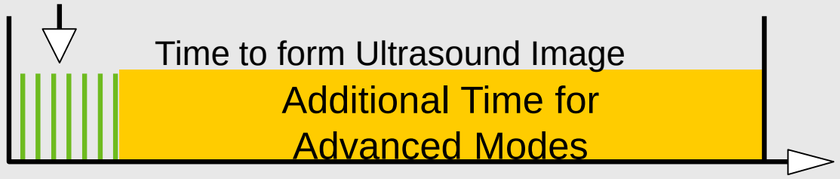

Large zone acquisition

10X faster

Software-based

Data retained

Both premium image quality and portability

Catheter Specification Comparison

	ViewFlex Xtra ICE Catheter	**Siemens AcuNav Ultrasound Catheter**
Catheter Dimension	9 F	8 F, 10 F
Minimum Introducer	10 F	9 F (for 8 F catheter) 11 F (for 10 F catheter)
Transducer type	64 element phased array	64 element phased array
Usable Length	90 cm	90 cm
Steering	Anterior/Posterior, Left/Right	Anterior/Posterior, Left/Right
Automatic Steering Lock	Yes	No
Manufacturer Console Compatibility	Zonare, Philips	Siemens, GE
Requires sterile sleeve	No	Yes
Color Doppler	Yes	Yes
Maximum Field of Depth	18 cm	15 cm

CAMPI D’APPLICAZIONE ICE

1) Monitoraggio della puntura transettale
2) Chiusura difetti interatriali
3) Impianto di valvole percutanee e valvuloplastiche
4) Ablazione di aritmie complesse per monitoraggio procedura e complicanze
5) Estrazione di cateteri e diagnosi di endocardite
6) Biopsia endomiocardica

- 7) Chiusura percutanea dell’auricola?

Viste base ice

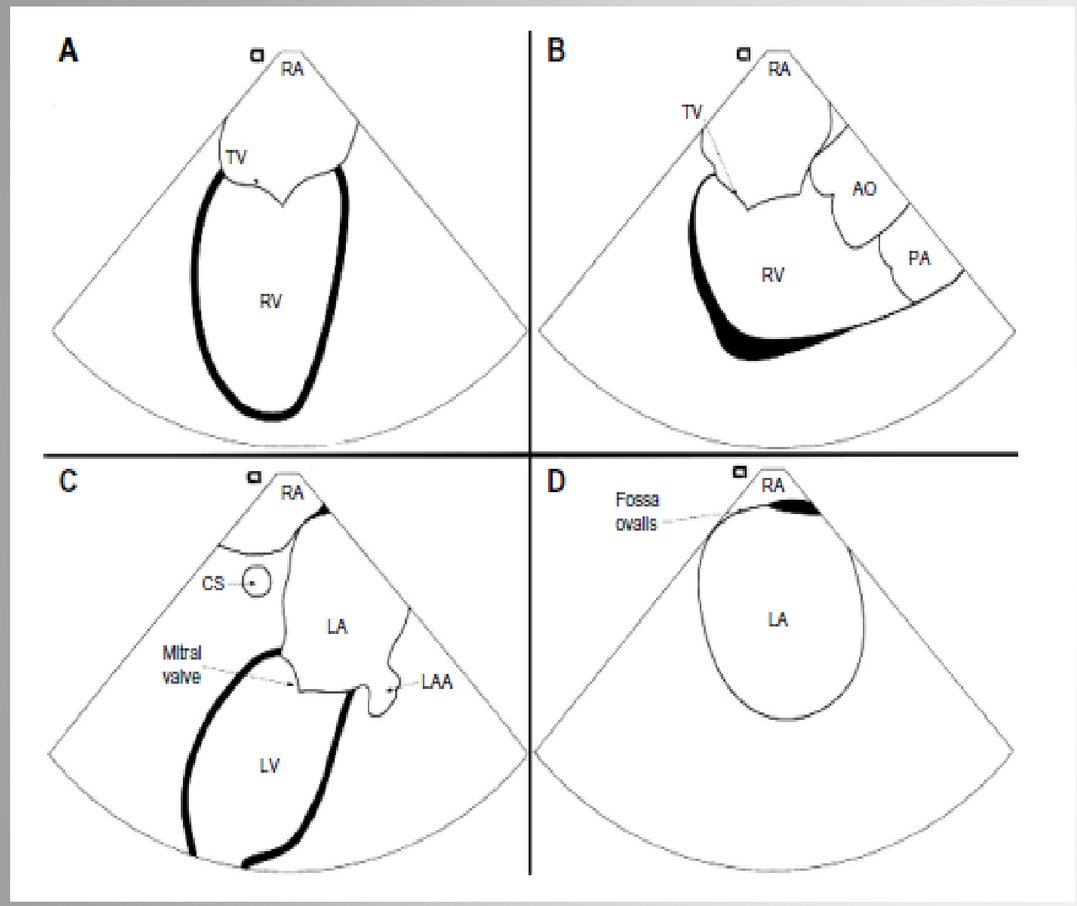

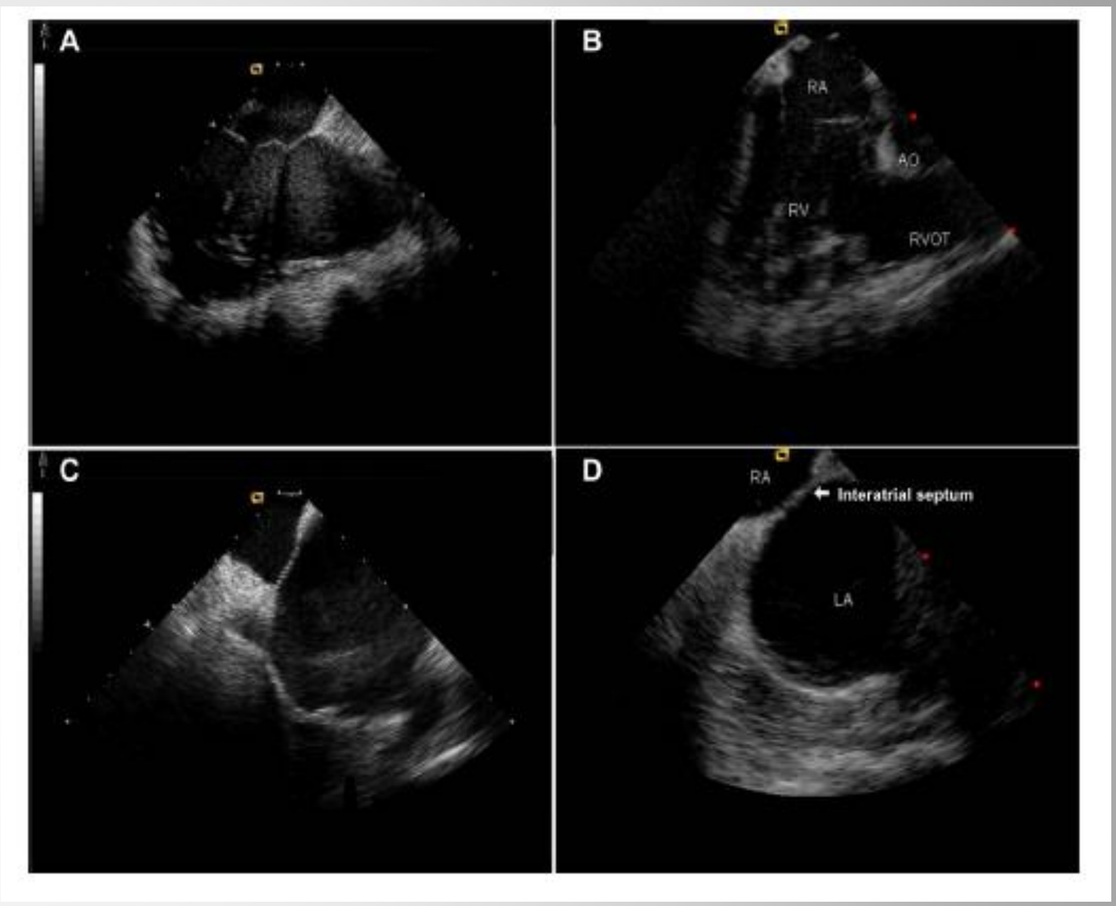

#3: Atrial / Septal View

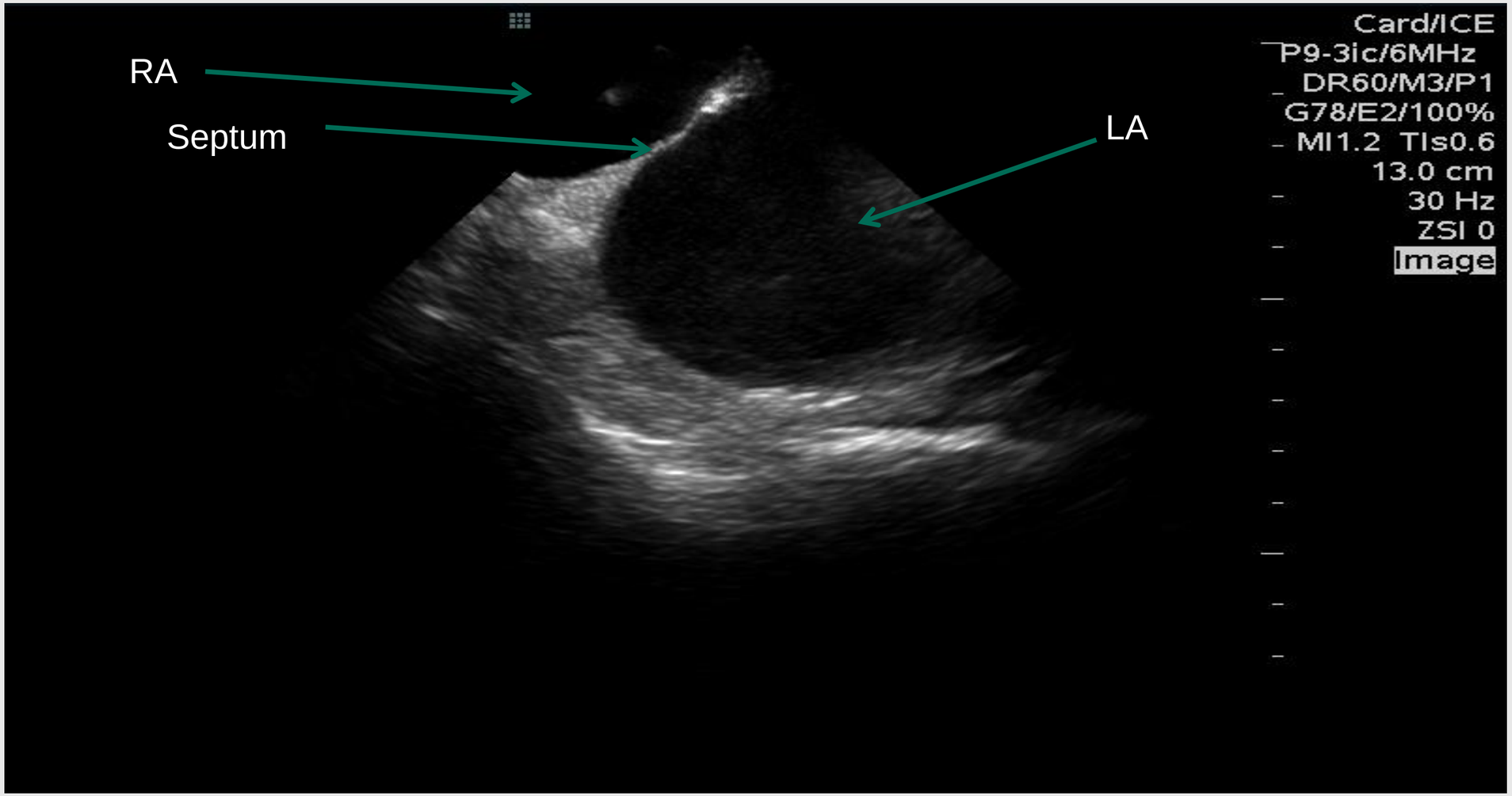

#4: FO, Right Atrium, CS, Left Atrium

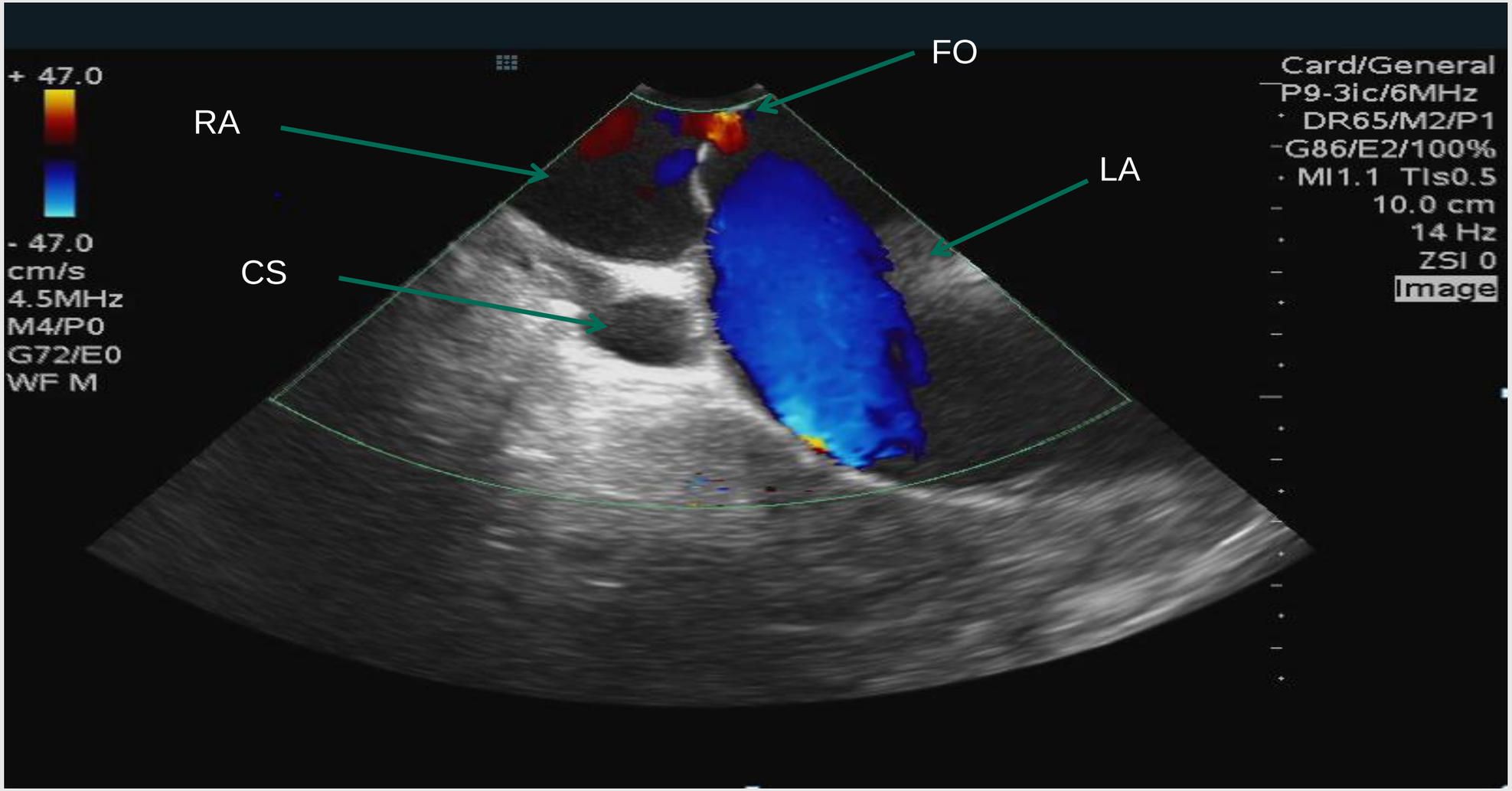

VANTAGGI ICE

- ICE usato in pazienti svegli o lievemente sedati
- Non rischio di lesioni esofagee (pz. con varici esofagee)
- riduzione dei tempi di scopia e procedurali
- riduzione del personale impiegato (anestesista, cardiologo ecografista)

SVANTAGGI ICE

- Costo
- performance sovrapponibili a TEE?

RUOLO DELL'ECOGRAFIA NELLA CHIUSURA DELL'AURICOLA

1) PRE: escludere trombi endocavitari, valutare morfologia e dimensioni LAA

ECO TRANSESOFAGEO

2) DURANTE: monitoraggio puntura transettale

valutazione dimensioni auricola

monitoraggio durante manovre di posizionamento/rilascio

ECO TRANSESOFAGEO/ICE

3) POST: valutazione leaks, trombosi device

ECO TRANSESOFAGEO

RUOLO DELL'ECOGRAFIA NELLA CHIUSURA DELL'AURICOLA

- PRE: misure di larghezza (ostio) e profondità per scelta del device
- ICE non permette semplice misura di profondita' (difficile visualizzazione)

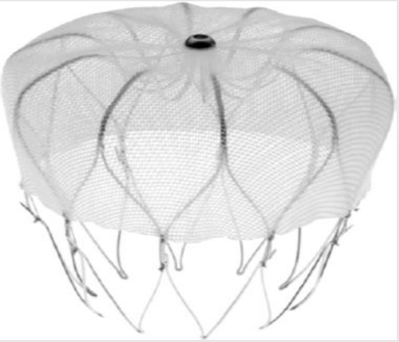

Watchman: necessaria profondità adeguata

Amplatzer: profondità meno rilevante per minor ingombro

IMMAGINI ICE ATRIO SINISTRO

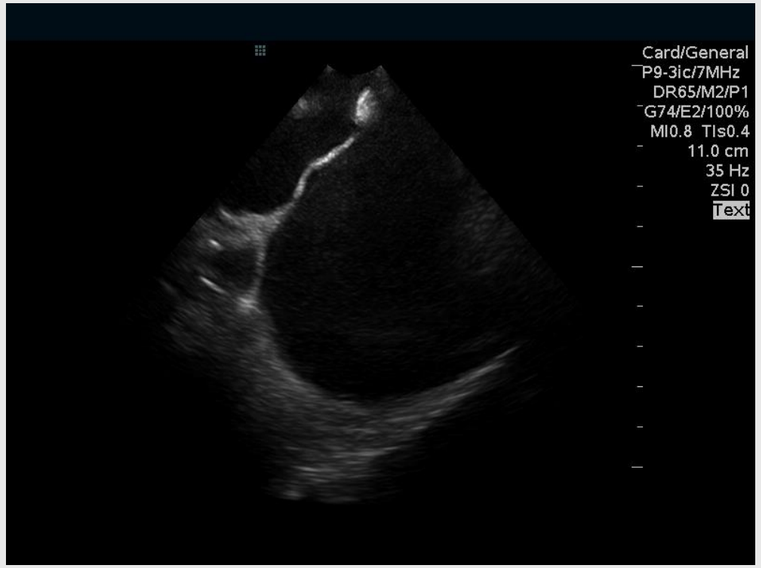

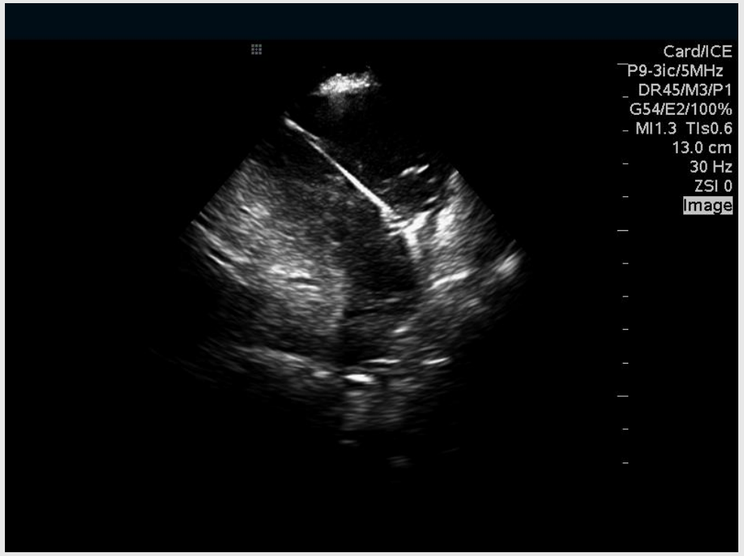

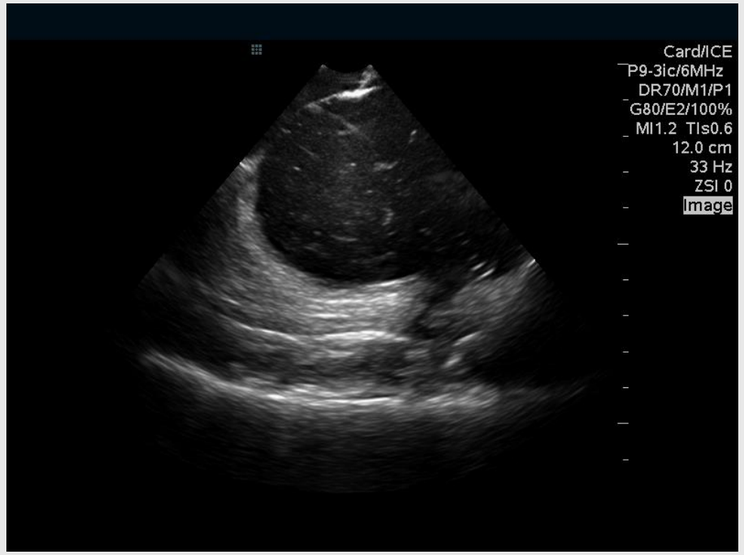

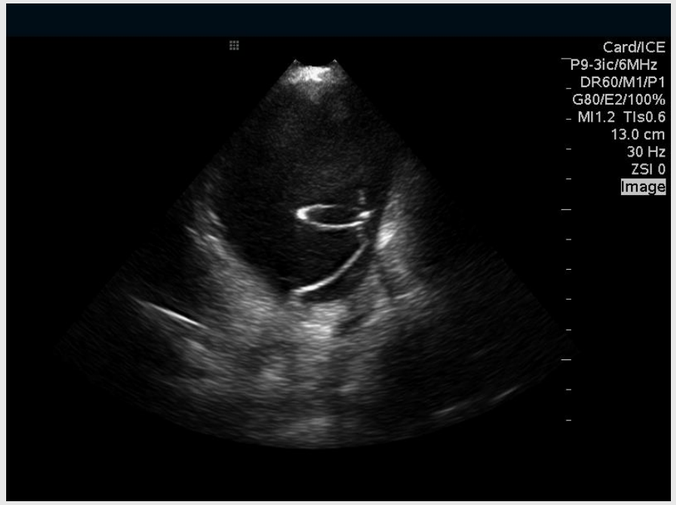

LA IMAGING BY ICE (ABLATION)

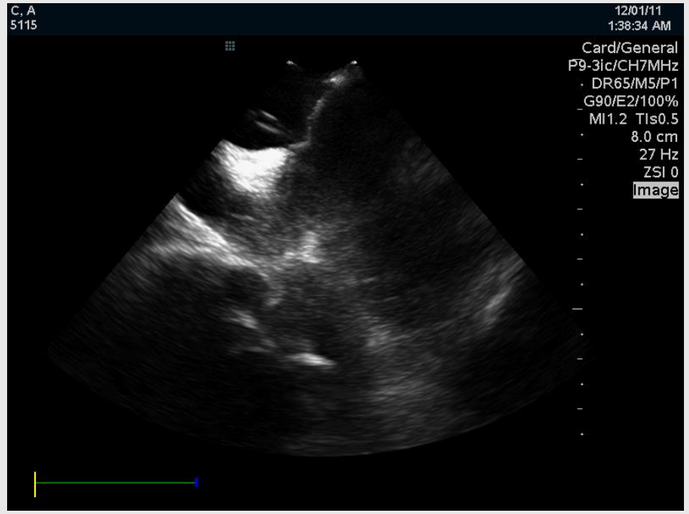

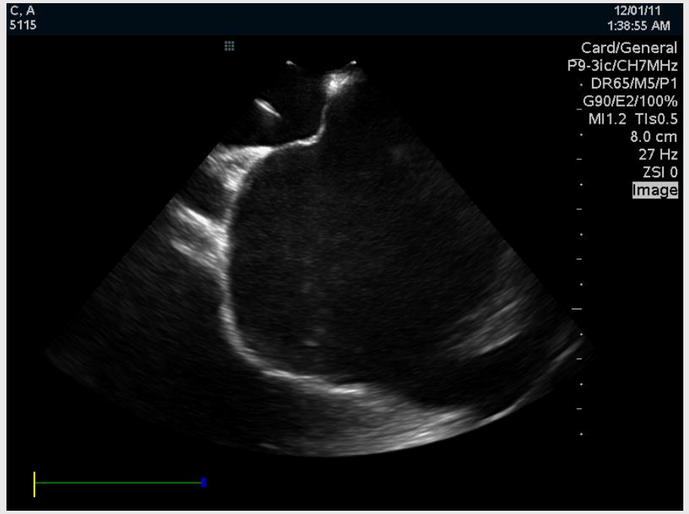

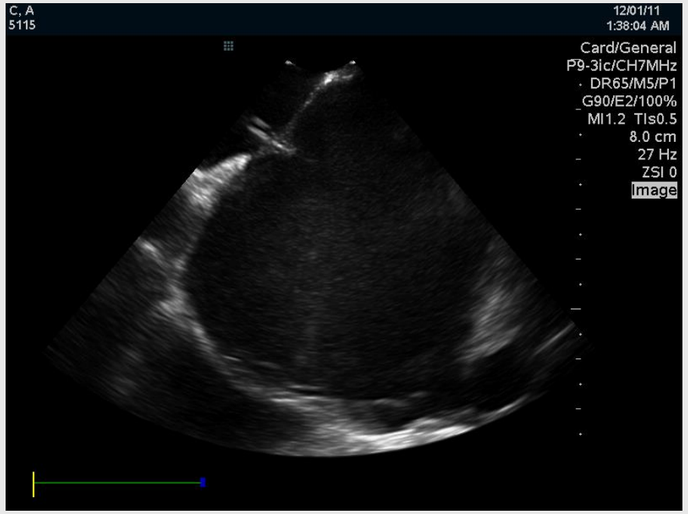

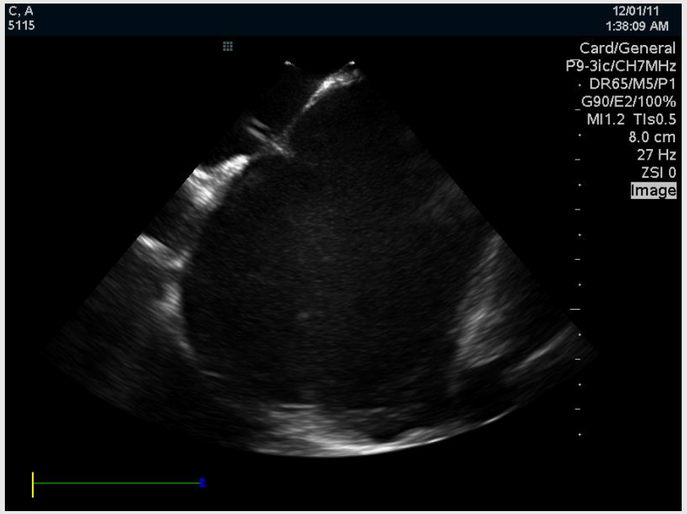

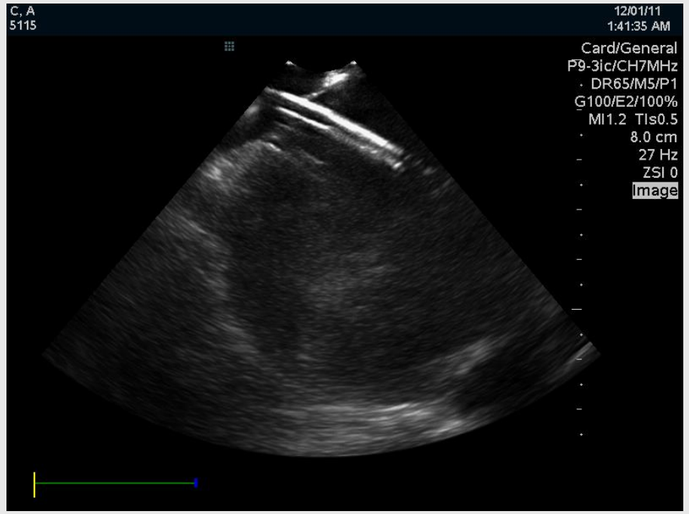

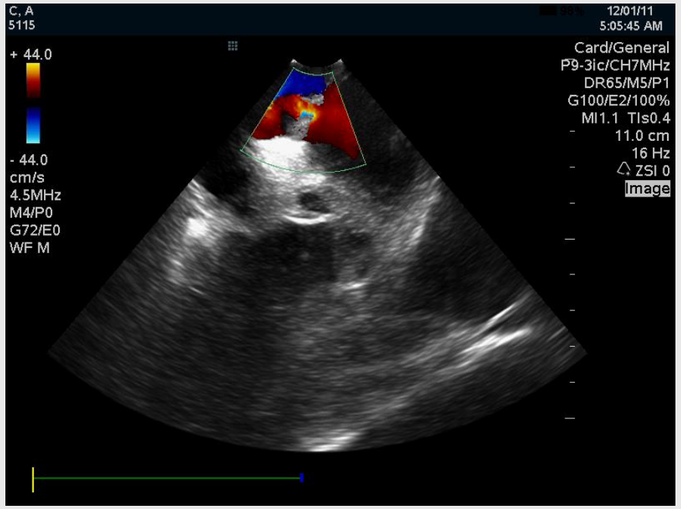

POSIZIONAMENTO ICE PER VISUALIZZAZIONE LAA

- Atrio destro: standard, visualizzazione non ottimale
- RVOT, ramo sinistro art. polmonare: agevole, miglior visualizzazione LAA
- CS: posizionamento delicato, con sheat in CS
- Atrio sinistro: attraverso transsettale

a. Adx
b. RVOT
c. PA sx

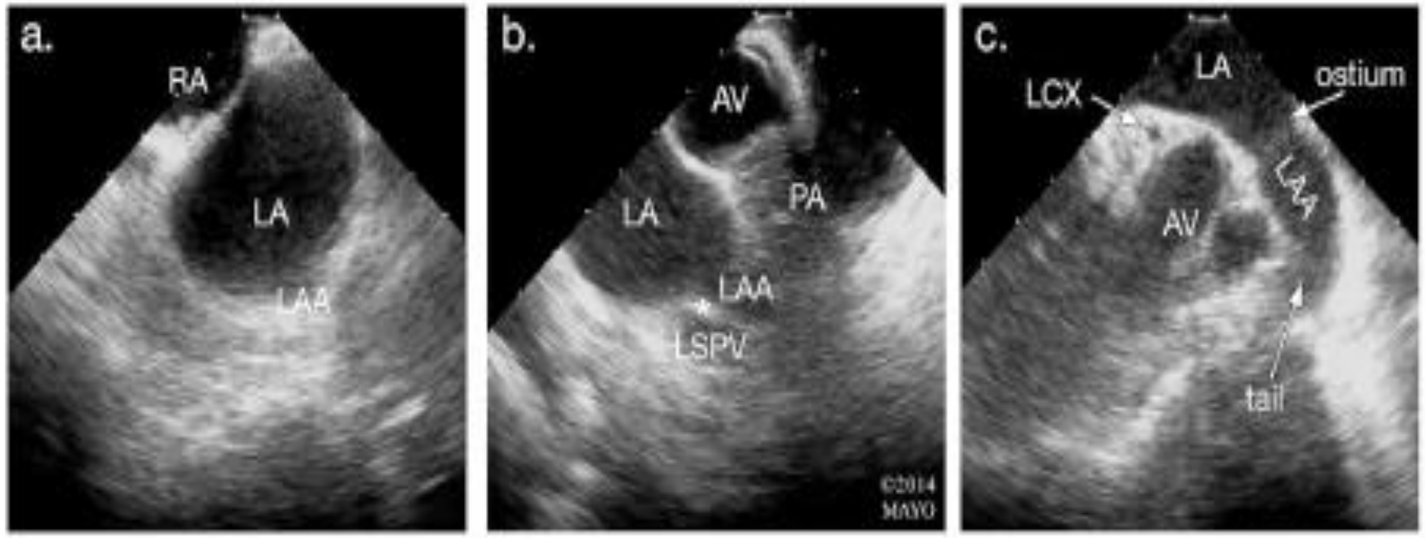

JACC: CARDIOVASCULAR INTERVENTIONS
VOL. 7, NO. 9, 2014
© 2014 BY THE AMERICAN COLLEGE OF CARDIOLOGY FOUNDATION
ISSN 1936-8798/$36.00
PUBLISHED BY ELSEVIER INC.
http://dx.doi.org/10.1016/j.jcin.2014.04.014

Periprocedural Intracardiac Echocardiography for Left Atrial Appendage Closure

A Dual-Center Experience

Sergio Berti, MD,* Umberto Paradossi, MD,* Francesco Meucci, MD,† Giuseppe Trianni, MD,* Apostolos Tzikas, MD,‡ Marco Rezzaghi, MD,* Miroslava Stolkova, MD,† Cataldo Palmieri, MD,* Fabio Mori, MD,† Gennaro Santoro, MD†

121 pz TEE pre

ICE solo durante la procedura da Adx

Misure del device

Monitoraggio fasi procedurali

Successo tecnico 97%

Successo procedurale 113 pz (93.4%).

4 eventi avversi maggiori: 3 tamponamenti,1 TIA

Correlazione significativa tra misure effettuate con ICE ed angio (r=0.94, p < 0.0001).

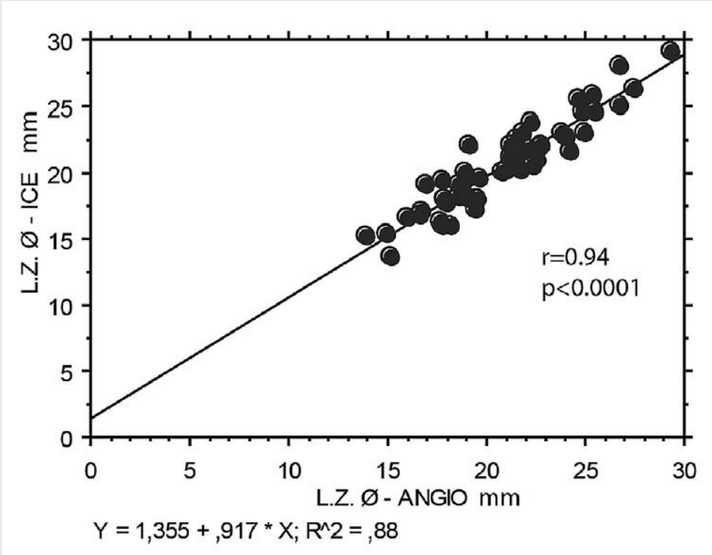

ICE FOR LAA CLOSURE

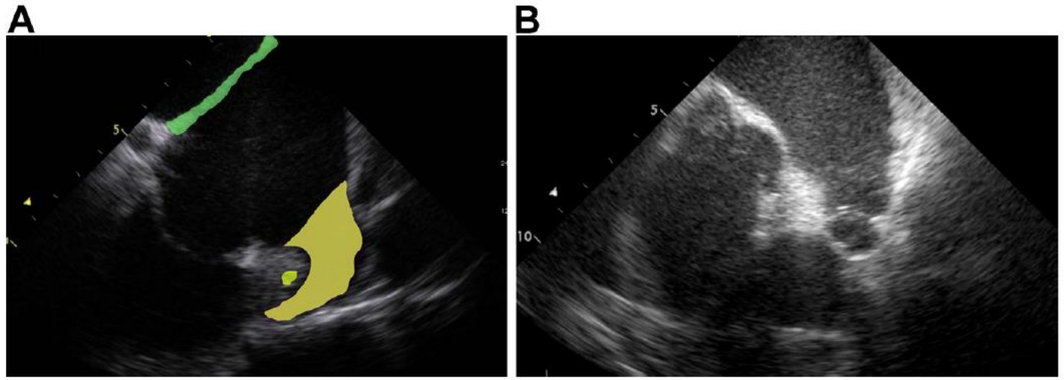

View of the LAA From the Right Atrium and CS

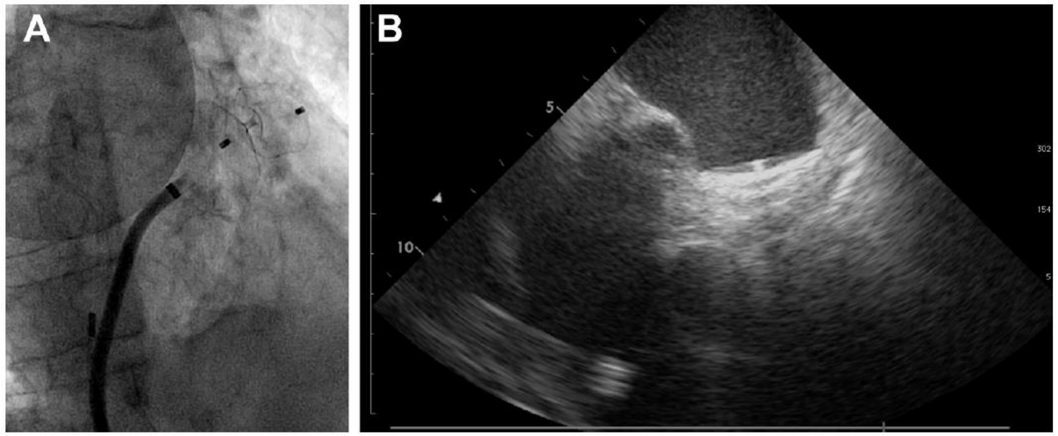

View of the APC Correctly Implanted Seen by Fluoroscopy and ICE

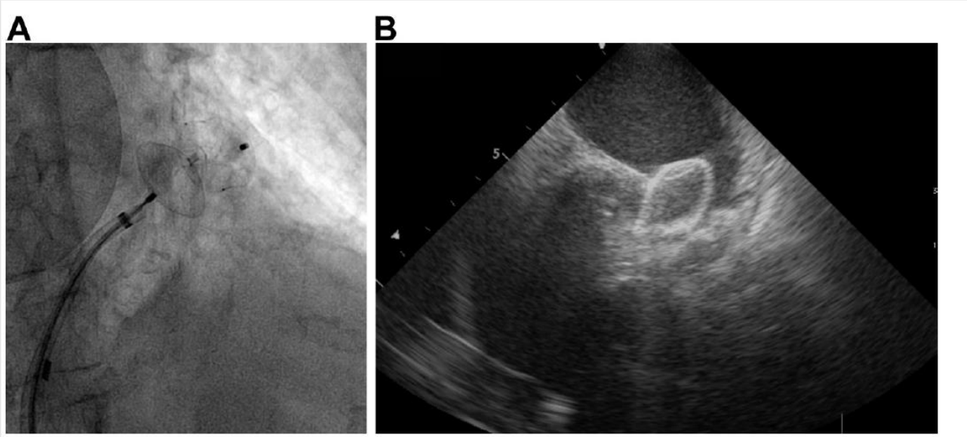

Traction Test Seen by Fluoroscopy and ICE

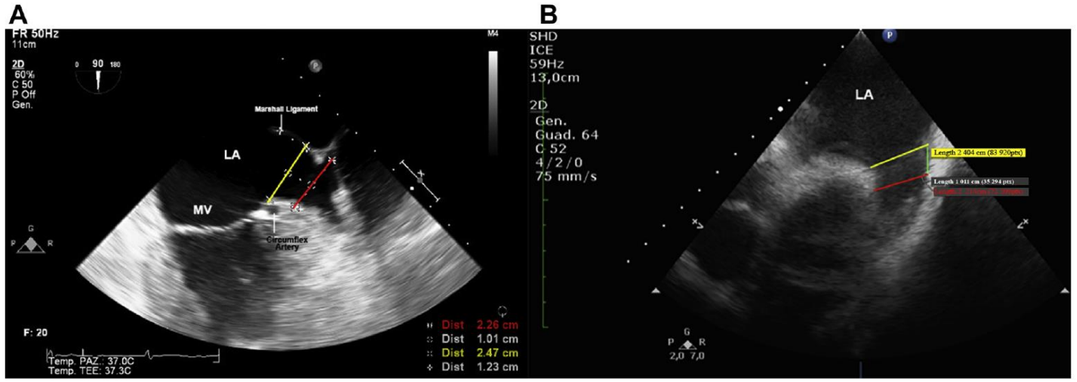

FIGURE 6 LAA Measurements

ICE FOR LAA CLOSURE

ORIGINAL RESEARCH

American Heart Association | American Stroke Association

Left Atrial Appendage Closure Under Intracardiac Echocardiographic Guidance: Feasibility and Comparison With Transesophageal Echocardiography

Yae Matsuo, MD;* Petr Neuzil, MD, PhD;* Jan Petru, MD; Milan Chovanec, MD; Marek Janotka, MD; Subbarao Choudry, MD; Jan Skoda, MD; Lucie Sediva, MD; Masahiko Kurabayashi, MD, PhD; Vivek Y. Reddy, MD*

Background—Transcatheter left atrial appendage closure is an alternative therapy for stroke prevention in atrial fibrillation patients. These procedures are currently guided with transesophageal echocardiography and fluoroscopy in most centers. As intracardiac echocardiography (ICE) is commonly used in other catheter-based procedures, we sought to determine the safety and effectiveness of intracardiac echocardiography–guided left atrial appendage closure with the Watchman device.

Methods and Results—A total of 27 patients (11 males, 77.0±8.5 years) with atrial fibrillation receiving Watchman left atrial appendage closure under intracardiac echocardiography guidance at a single center were investigated. All patients were implanted successfully. There were no major procedural complications. The overall procedure-related complication rate was 14.8%, mainly due to access site hematoma. Transesophageal echocardiography demonstrated successful closure of the left atrial appendage in all patients at 45 days after device implant.

Conclusions—Transcatheter left atrial appendage closure with intracardiac echocardiography guidance is safe and feasible.
(*J Am Heart Assoc.* 2016;5:e003695 doi: 10.1161/JAHA.116.003695)

Key Words: intracardiac echocardiography • left atrial appendage closure • stroke prevention

ICE efficace nel guidare la procedura anche con dispositivo WATCHMAN

EcoTEE pre e al termine della procedura

ICE in atrio destro

Misure non del tutto sovrapponibili ma non differenze deteminanti nel sizing del dispositivo

CHIUSURA AURICOLA CON ICE

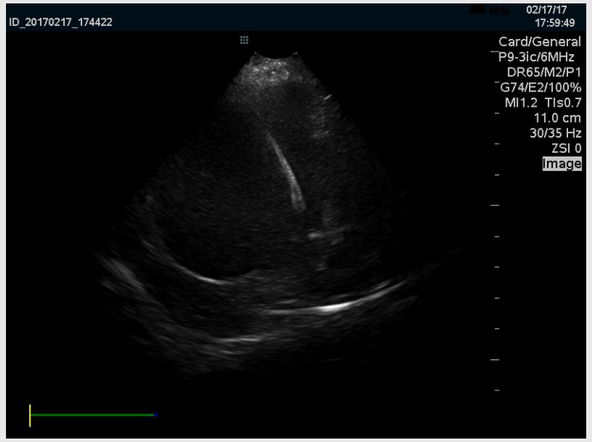

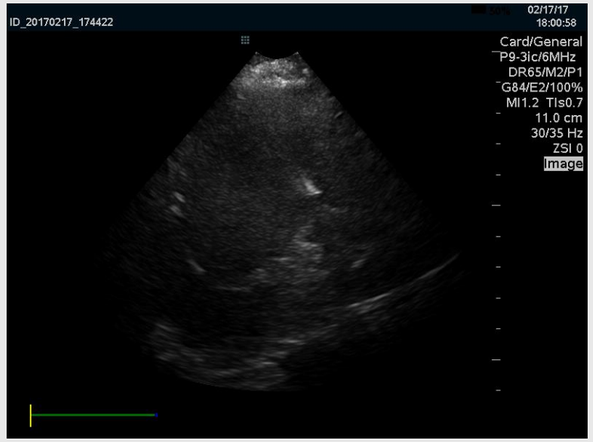

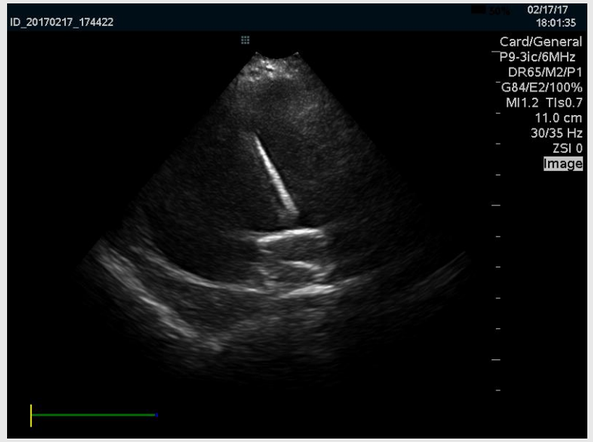

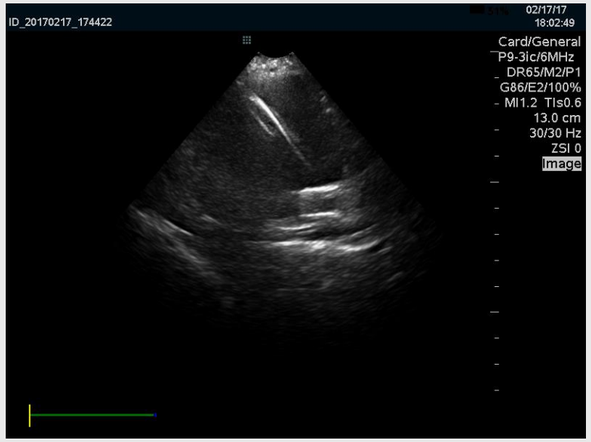

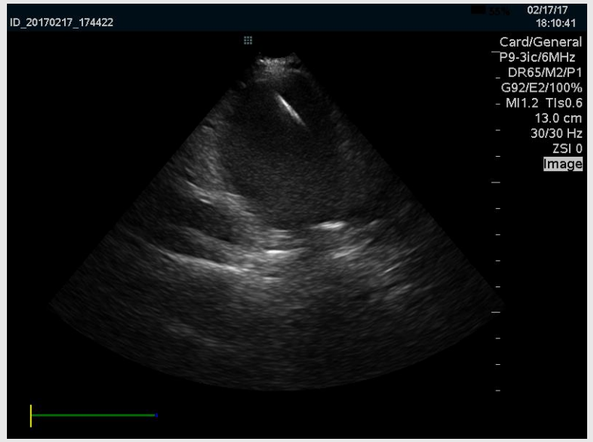

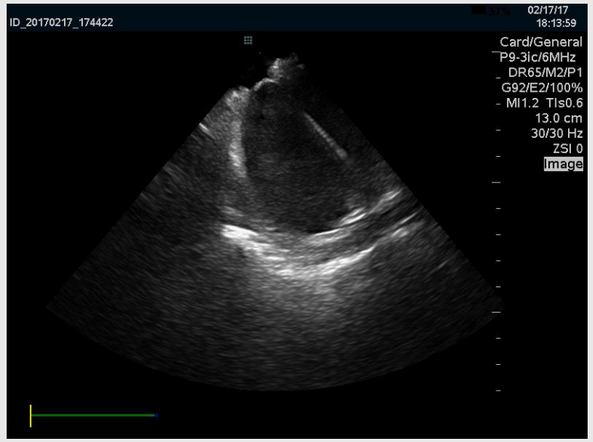

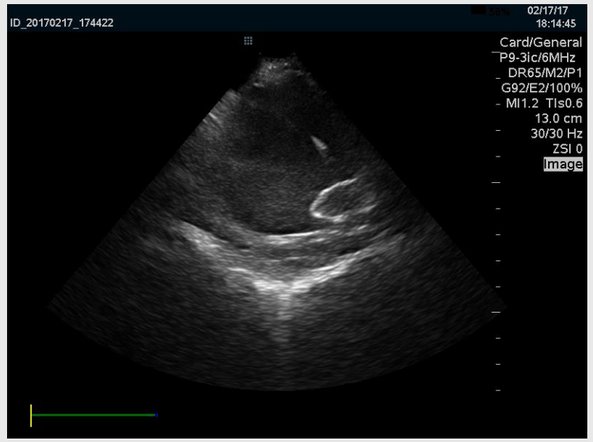

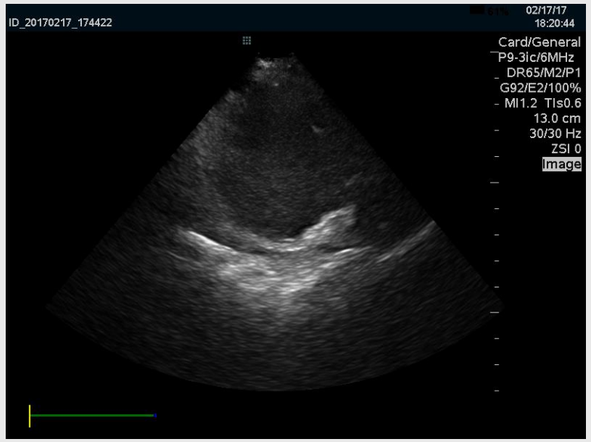

SONDA ICE IN ATRIO SINISTRO

An Alternative Transseptal Intracardiac Echocardiography Strategy to Guide Left Atrial Appendage Closure: The First Described Case

GAETANO FASSINI, M.D., ANTONIO DELLO RUSSO, M.D., PH.D., SERGIO CONTI, M.D., and CLAUDIO TONDO, M.D., PH.D.

From the Cardiac Arrhythmia Research Centre, Centro Cardiologico Monzino, Electrophysiology, Milan, Italy

Transseptal Intracardiac Echocardiography Strategy. Transesophageal echocardiography (TEE) is the standard imaging technique to guide device implantation for left atrial appendage (LAA) closure. Unfortunately, TEE was contraindicated in this patient due to the high risk of variceal hemorrhage. Critical information about the exact anatomic characteristics of the LAA can be obtained using intracardiac echocardiography (ICE). However, standard right-side views do not allow a complete visualization of the LAA: in particular, a reliable left circumflex coronary artery short axis view, relevant for device positioning, is not always achievable. Transseptal views of the LAA with ICE might be used in planning an appropriate intervention strategy for patients who are not suitable for TEE imaging. *(J Cardiovasc Electrophysiol, Vol. 25, pp. 1269-1271, November 2014)*

intracardiac echocardiography, left atrial appendage device closure

- Paziente con varici esofagee con controindicazione a TEE
- Da atrio dx visualizzazione inadeguata LAA
- ICE in atrio sinistro con transettale
- Misure con ICE
- Posizionamento Amplatzer Amulet
- Verifiche di stabilita', rilascio

MISURE DELL'OSTIO CON ICE E ANGIOGRAFIA

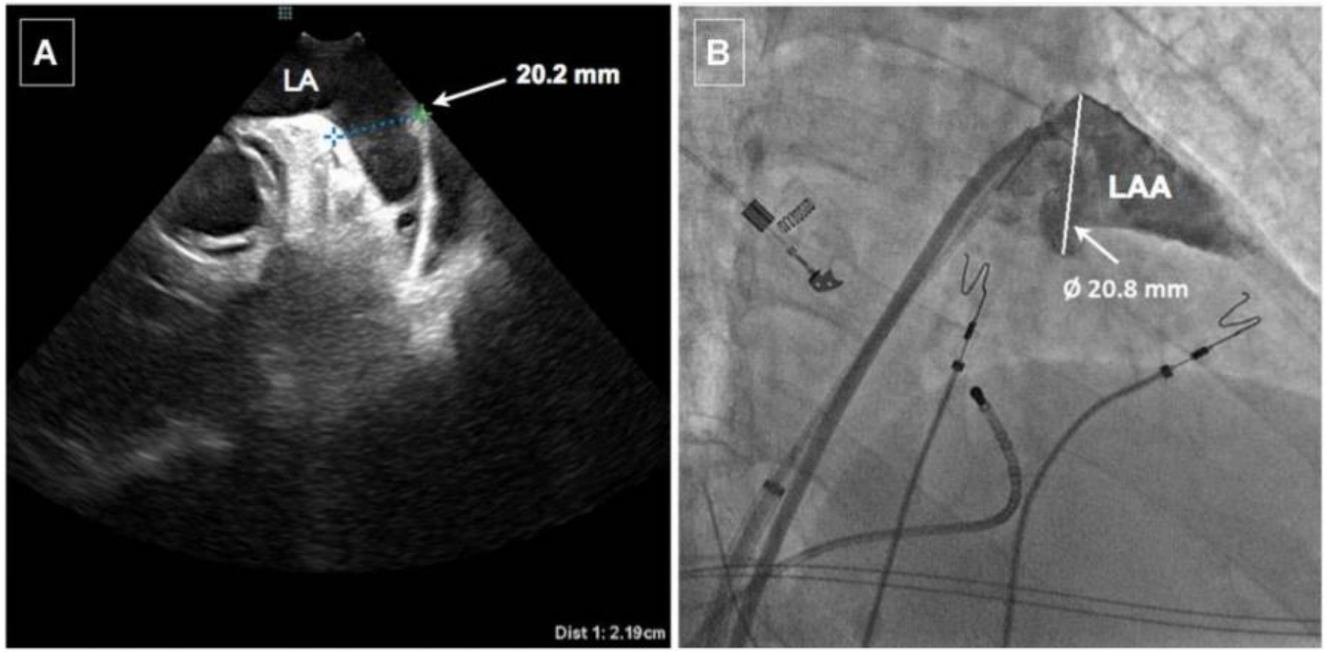

Figure 1. *The ostium of the LAA (arrows) measured by angiography and intracardiac echocardiography. Panel A: The appendage was imaged with the transducer placed in the LA. Panel B: Left atrial angiography by contrast injection through the sheath. LA = left atrial; LAA = left atrial appendage. For a high quality, full color version of this figure, please see Journal of Cardiovascular Electrophysiology's website: www.wileyonlinelibrary.com/journal/jce*

POSIZIONAMENTO AMULET

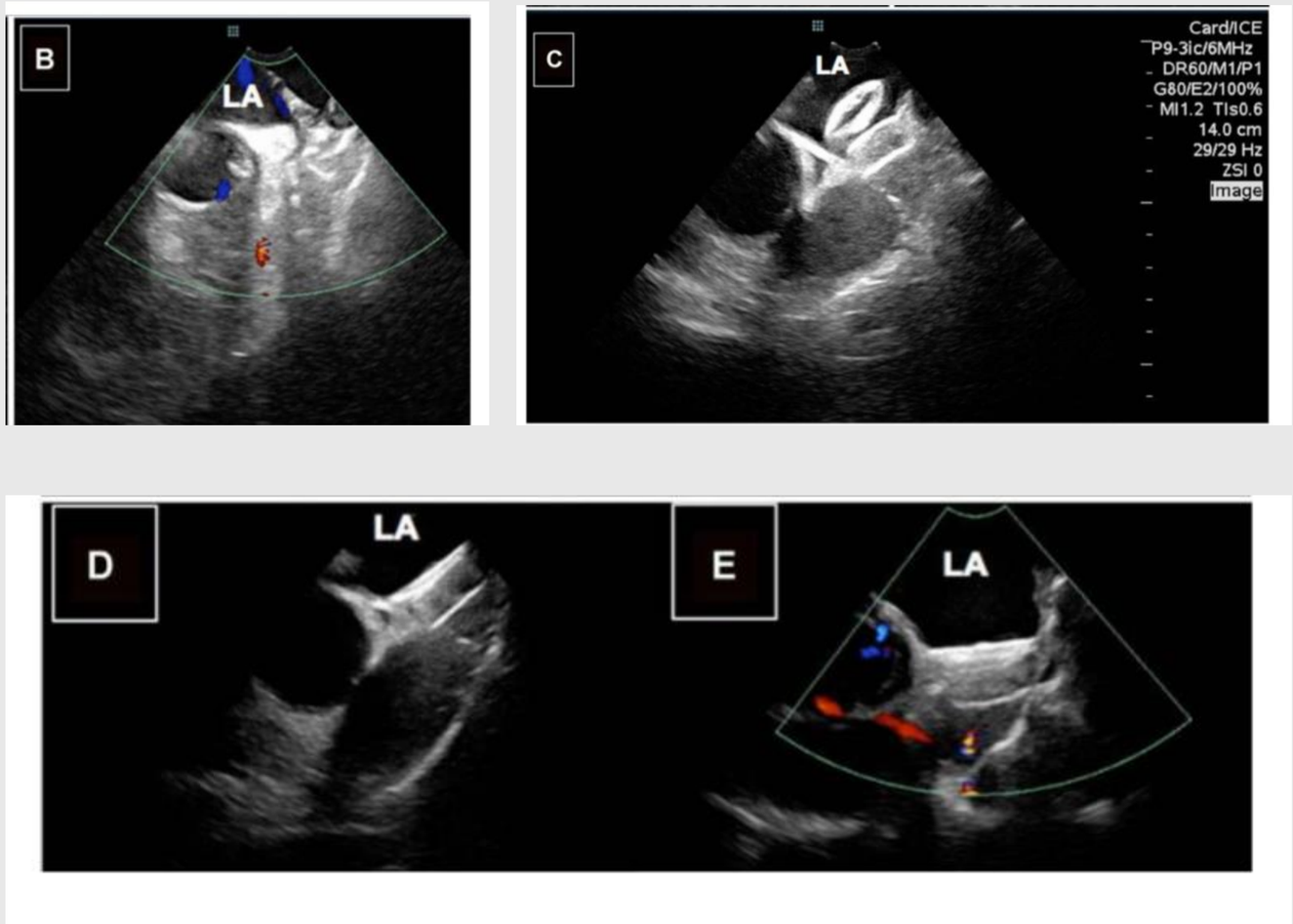

Posizionamento del lobo distale

Trazione manuale per verificare stabilita’

Rimozione del delivery

Conferma di corretto posizionamento, senza leaks

POSIZIONAMENTO DISPOSITIVO

CONFERMA CORRETTO POSIZIONAMENTO

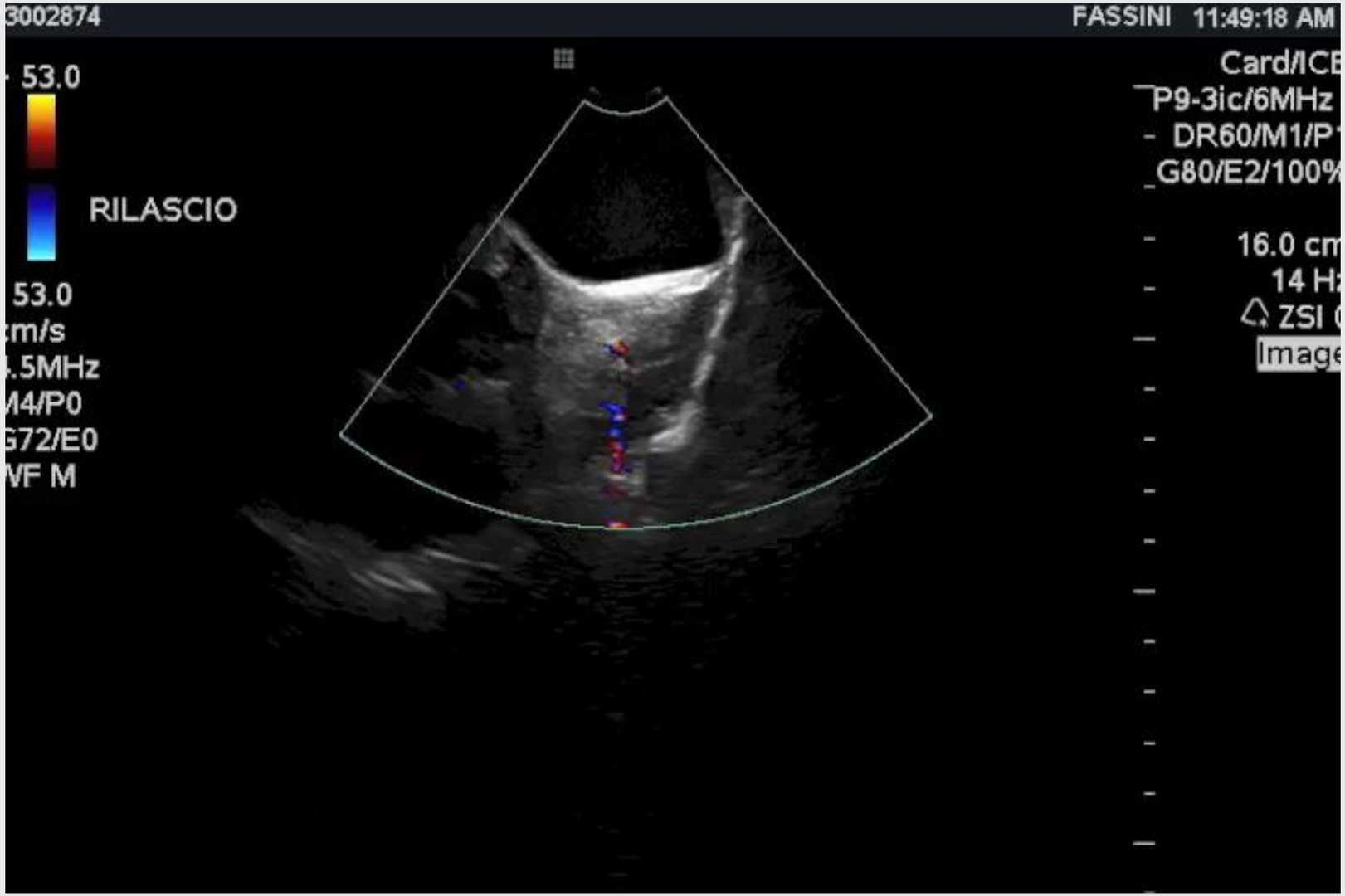

J Interv Card Electrophysiol (2011) 31:191–196
DOI 10.1007/s10840-011-9559-z

Analysis of the left atrial appendage morphology by intracardiac echocardiography in patients with atrial fibrillation

Dan Blendea · E. Kevin Heist · Stephan B. Danik · Conor Barrett · Jeremy N. Ruskin · Moussa Mansour

Received: 26 January 2011 / Accepted: 18 February 2011 / Published online: 1 April 2011
© Springer Science+Business Media, LLC 2011

LAA MEASUREMENTS (RA, CS, LA)

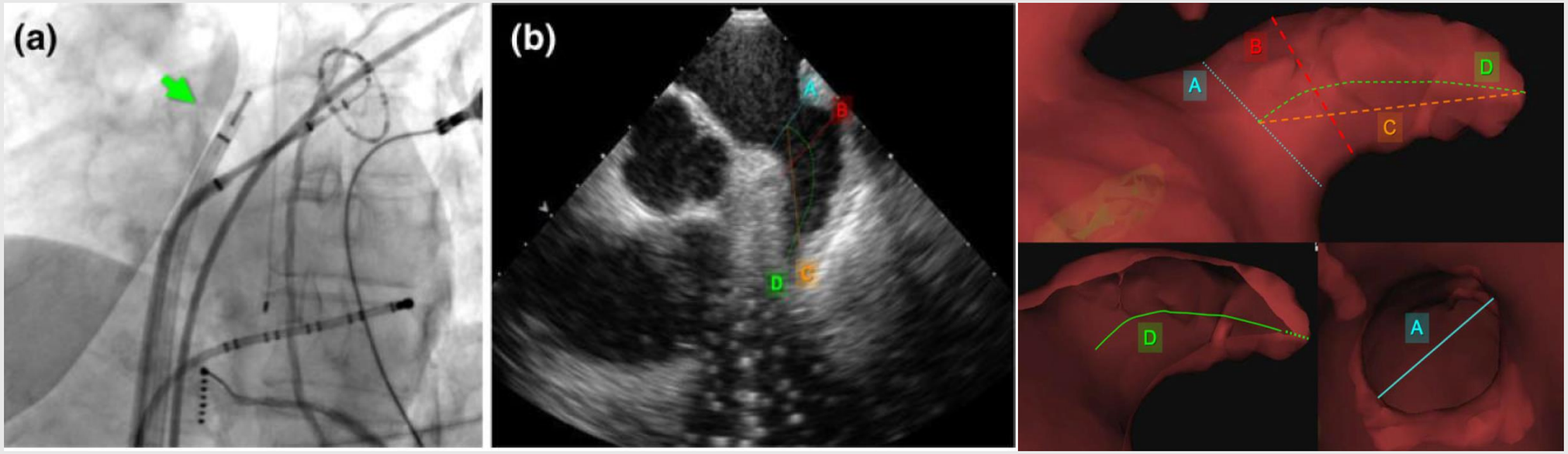

J Interv Card Electrophysiol (2011) 31:191–196

Table 2 Dimensions of the left atrial appendage

Variable	CT/MRI	ICE in LA	Limits of agreement with CT/MRI mean±SD (95% CI)
LAA ostium (mm)	26.7±4.5	24.0±4.3	2.8±3.1 (2.2 to 3.4)
LAA width (mm)	21.5±3.8	21.2±4.5	0.2±3.1 (−0.4 to 0.8)
LAA depth (mm)	33.2±4.6	31.8±4.3	1.4±2.0 (1.0 to 1.8)
LAA length (mm)	41.2±8.3	41.0±6.7	0.3±4.2 (−0.5 to 1.1)

LA ICE VS CT/MRI

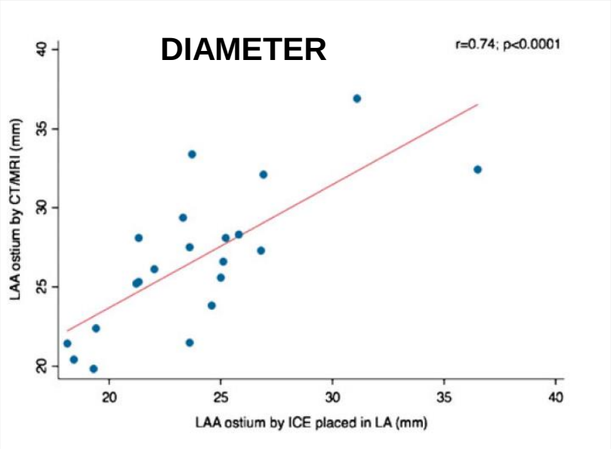

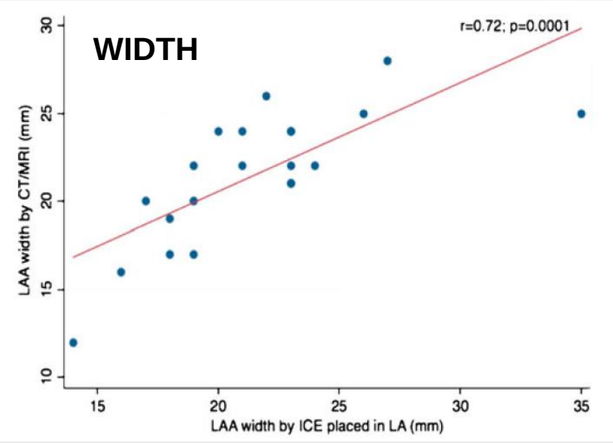

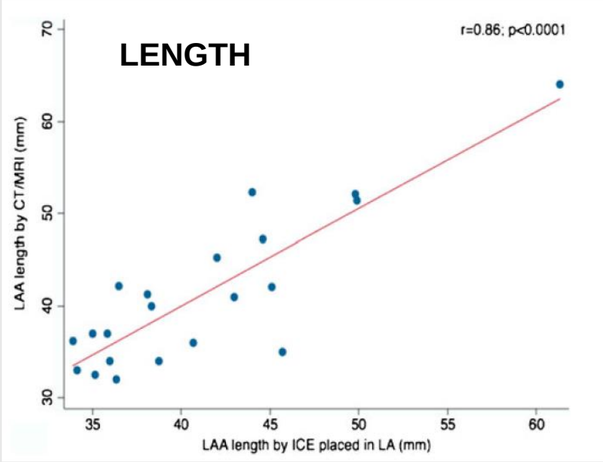

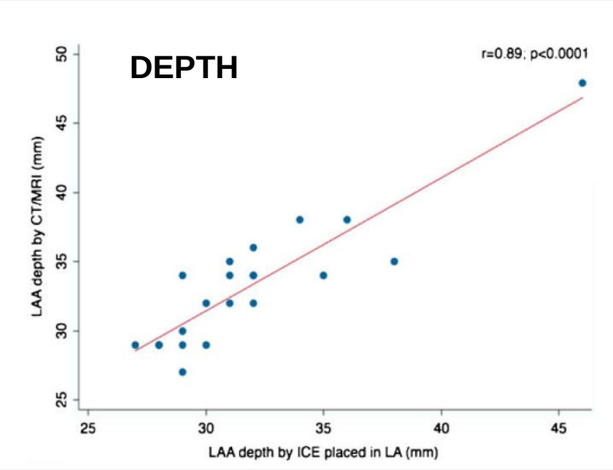

ICE in ADX permette visualizzazione LAA ma con misure meno attendibili rispetto a ASX in confronto con CT/MRI

LAA E ICE: CONCLUSIONI

- Impianto ICE guidato è fattibile e sicuro
- Efficace con entrambi i dispositivi (Amulet, Watchman)
- Diversi approcci possibili: atrio destro, RVOT, CS, art. polmonare, atrio sinistro
- Misure piu' affidabili in atrio sinitro
- Buona correlazione tra misure ICE e scopia e TEE (scelta del dispositivo), piu' precise se effettuate in atrio sinistro

LAA E ICE: CONCLUSIONI

- In quale paziente?
- Controindicazioni a TEE
- Controindicazioni a sedazione profonda/intubazione

- Vantaggi per il paziente:
- Non necessaria intubazione

- Vantaggi per il medico:
- Organizzazione semplificata (no anestesista, non ecocardiografista)
- Riduzione dell’esposizione radiologica globale (meno personale in S.O.)

LAA E ICE: CONCLUSIONI

- Svantaggi:

- Costo
- Visualizzazione a volte difficoltosa
- Accesso in atrio sx e permanenza in atrio sinistro di sonda ICE (rischio trombi?)
- Necessità di personale medico con adeguato training

METODICA UTILE E A VOLTE INDISPENSABILE PER POTER EFFETTUARE LA PROCEDURA